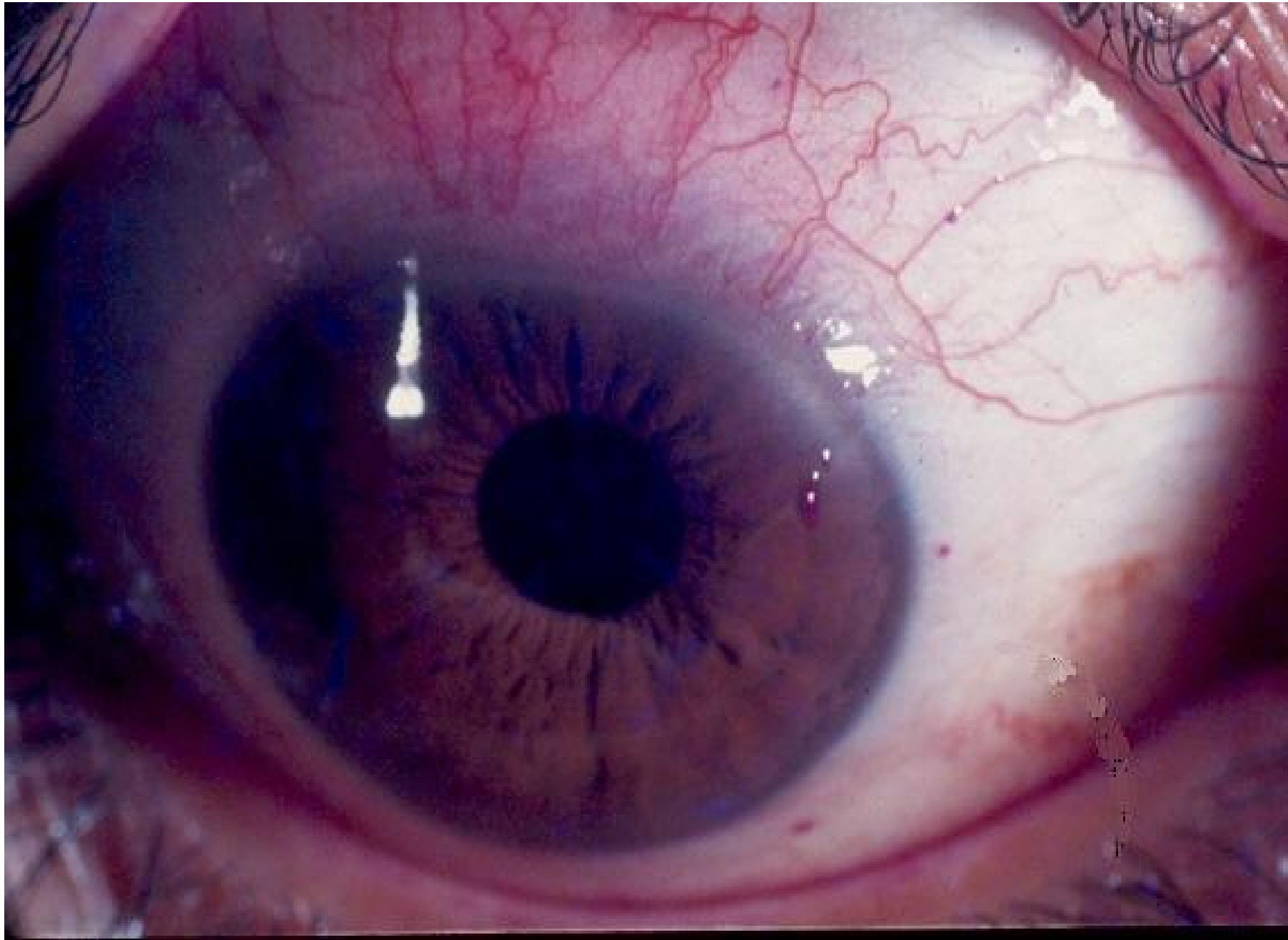
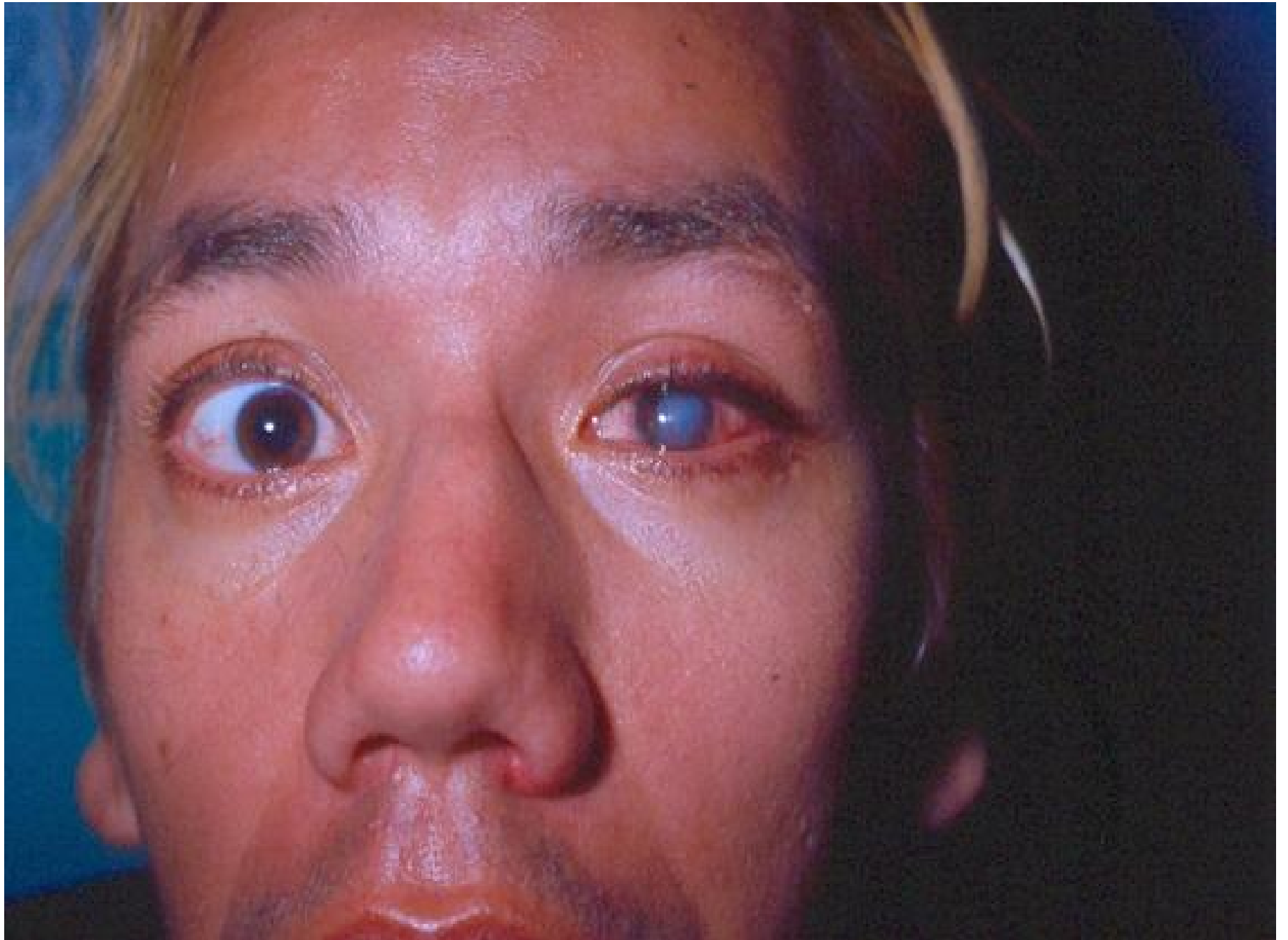

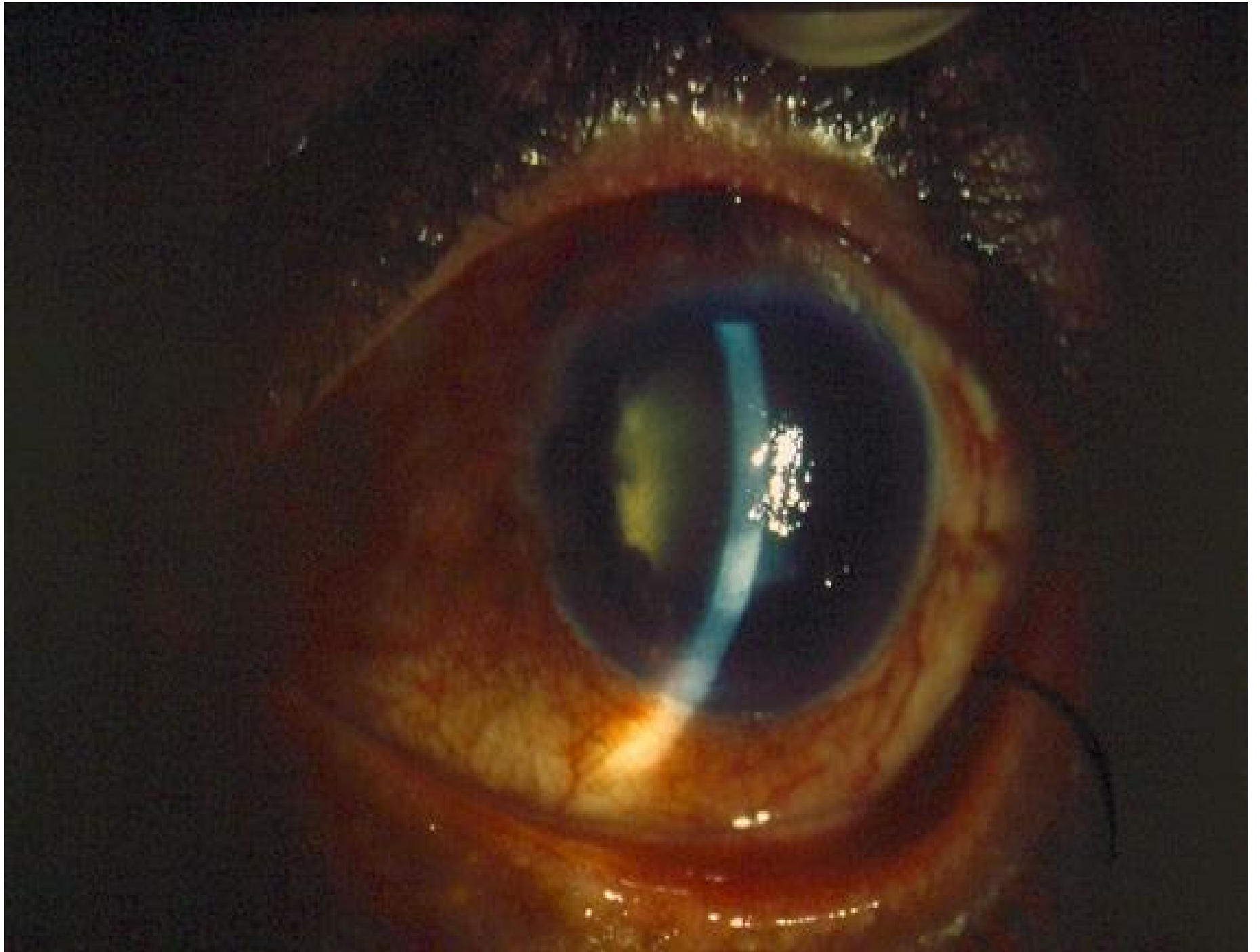


# OJO ROJO AGUDO

✦ Es grave ?

✦ Es leve ?





# OJO ROJO AGUDO

- ✦ **DEFINICIÓN:** hiperemia de los vasos visibles de la conjuntiva, epiesclera y esclera
- ✦ **ETIOLOGÍA:**
- ✦ conjuntiva
- ✦ córnea
- ✦ esclera-epiesclera
- ✦ iris y c. ciliar
- ✦ glaucoma agudo

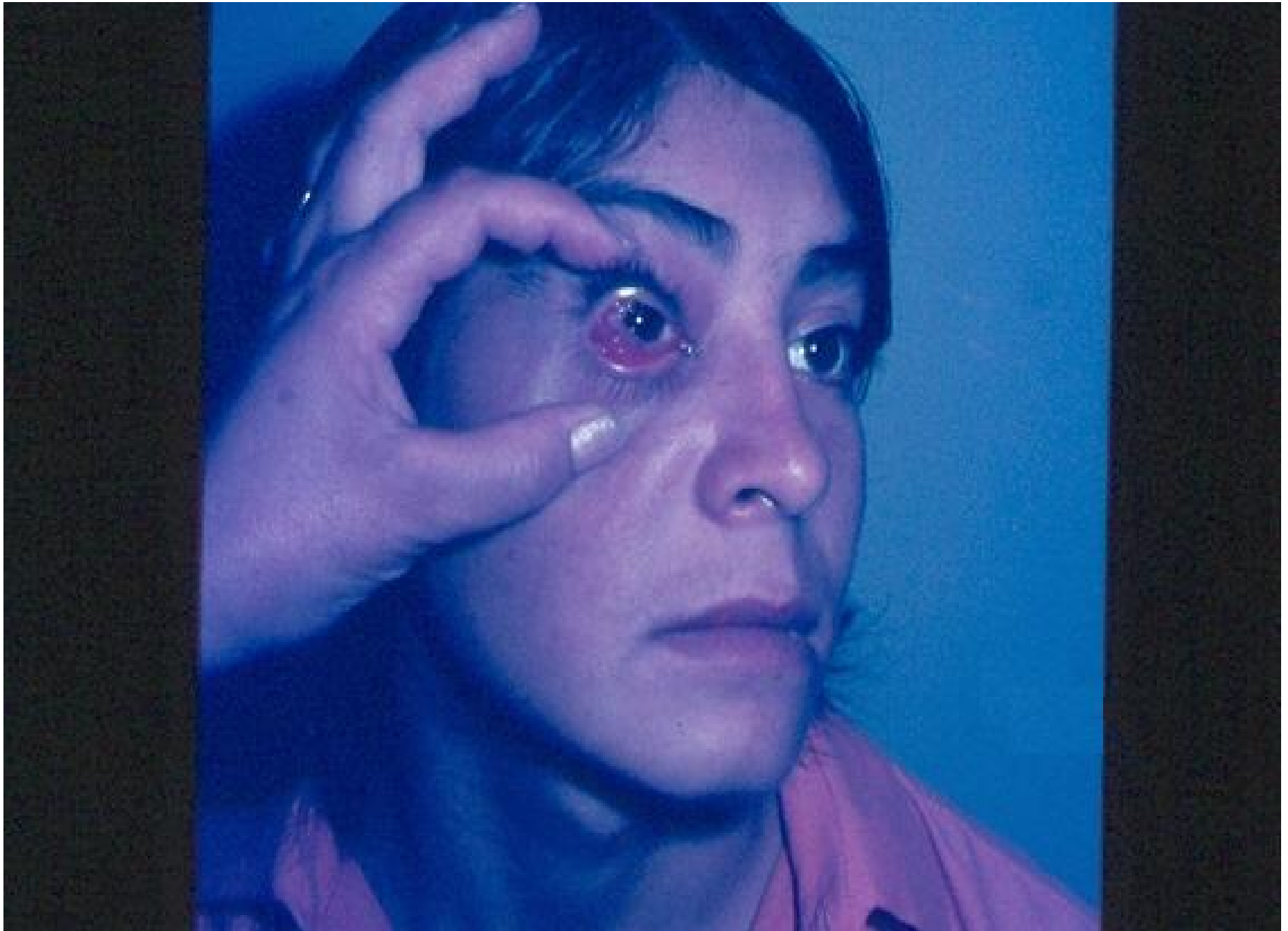# COMO EXAMINAR

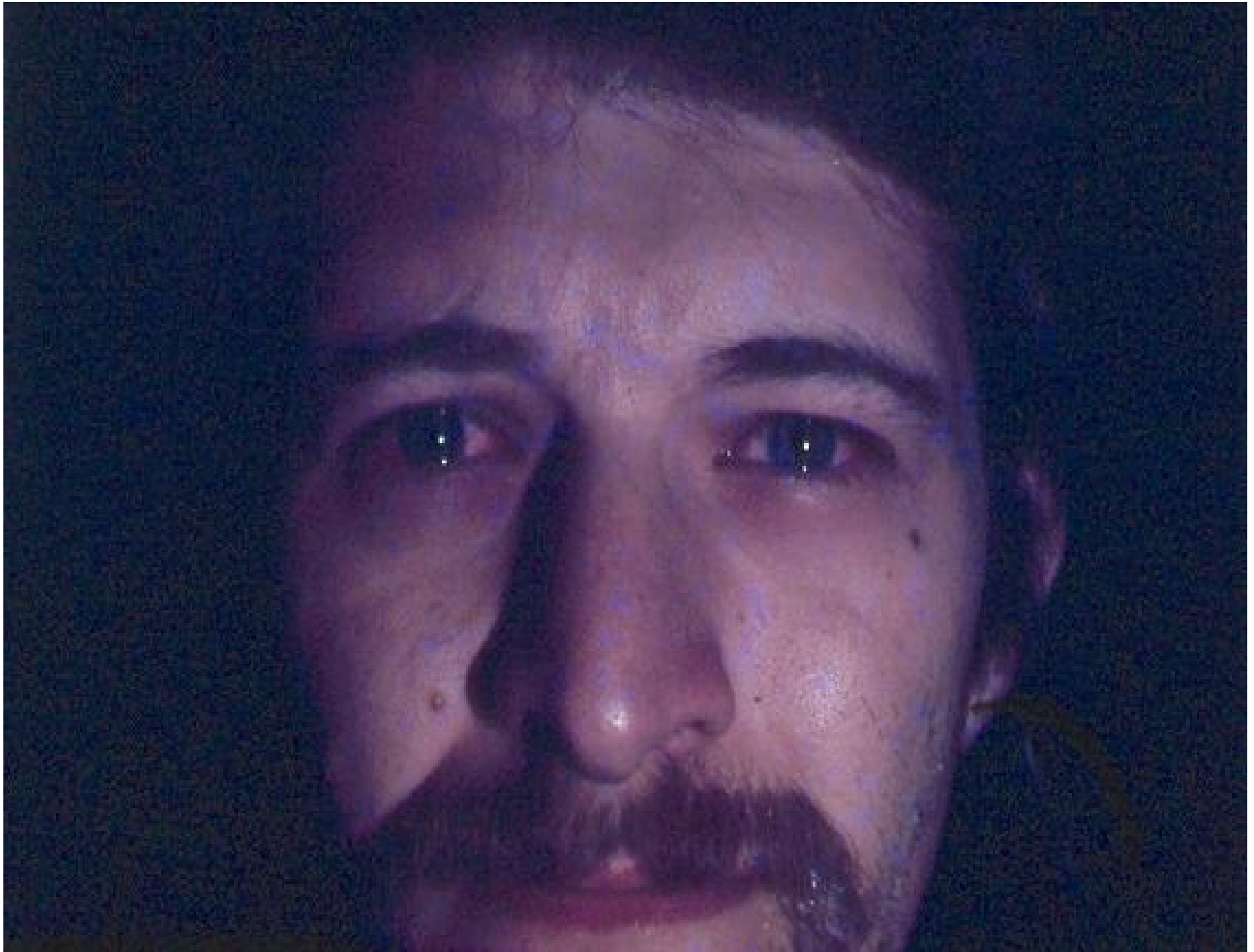- **CONGESTIÓN :Conjuntival, ciliar, mixta**
- **SECRECIÓN**
- **AGUDEZA VISUAL**
- **PRESIÓN OCULAR**
- **OPACIDADES Y TINCIÓN CORNEANA**
- **PROFUNDIDAD C.A.**
- **PUPILA**

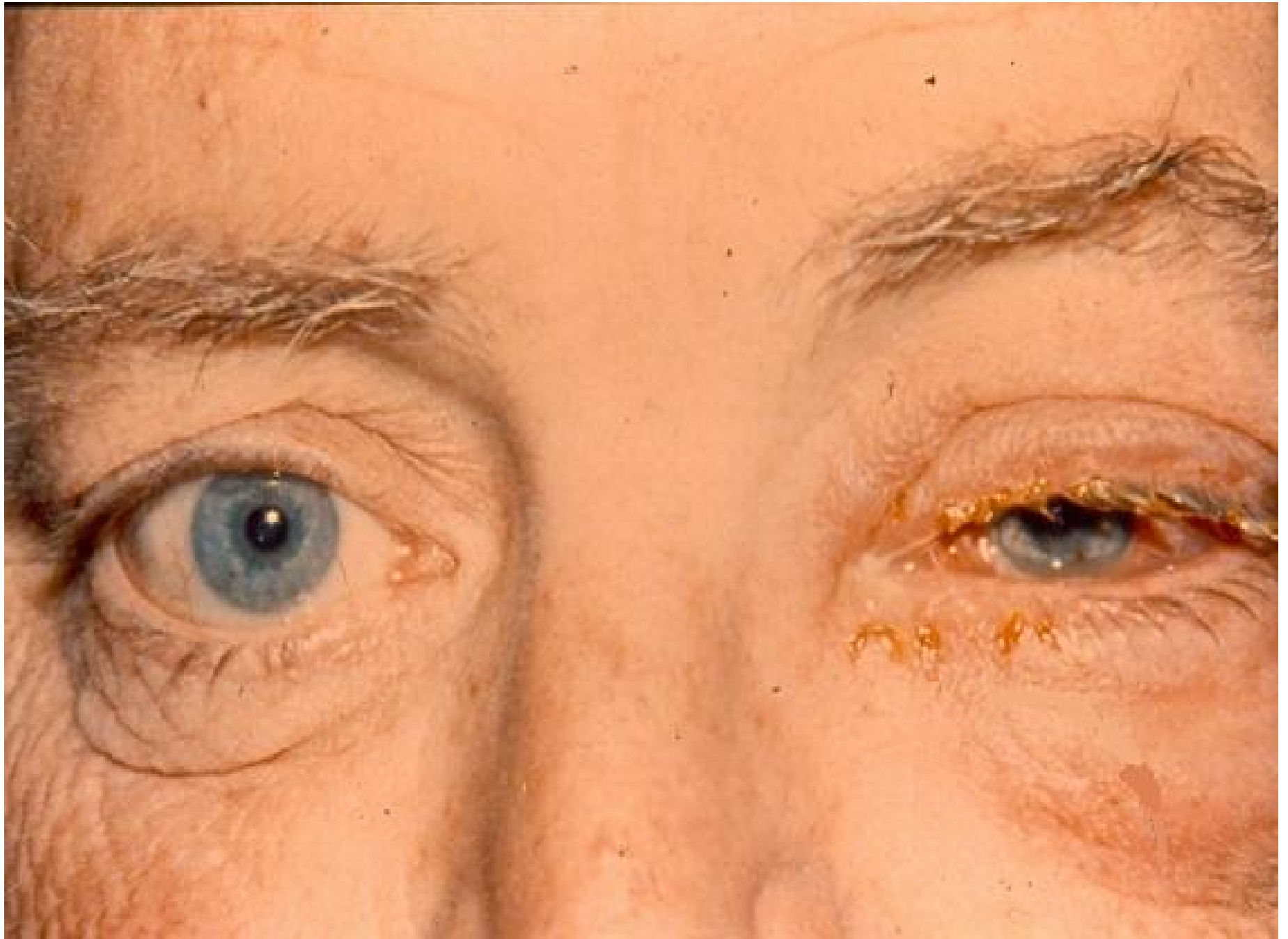# SINTOMAS

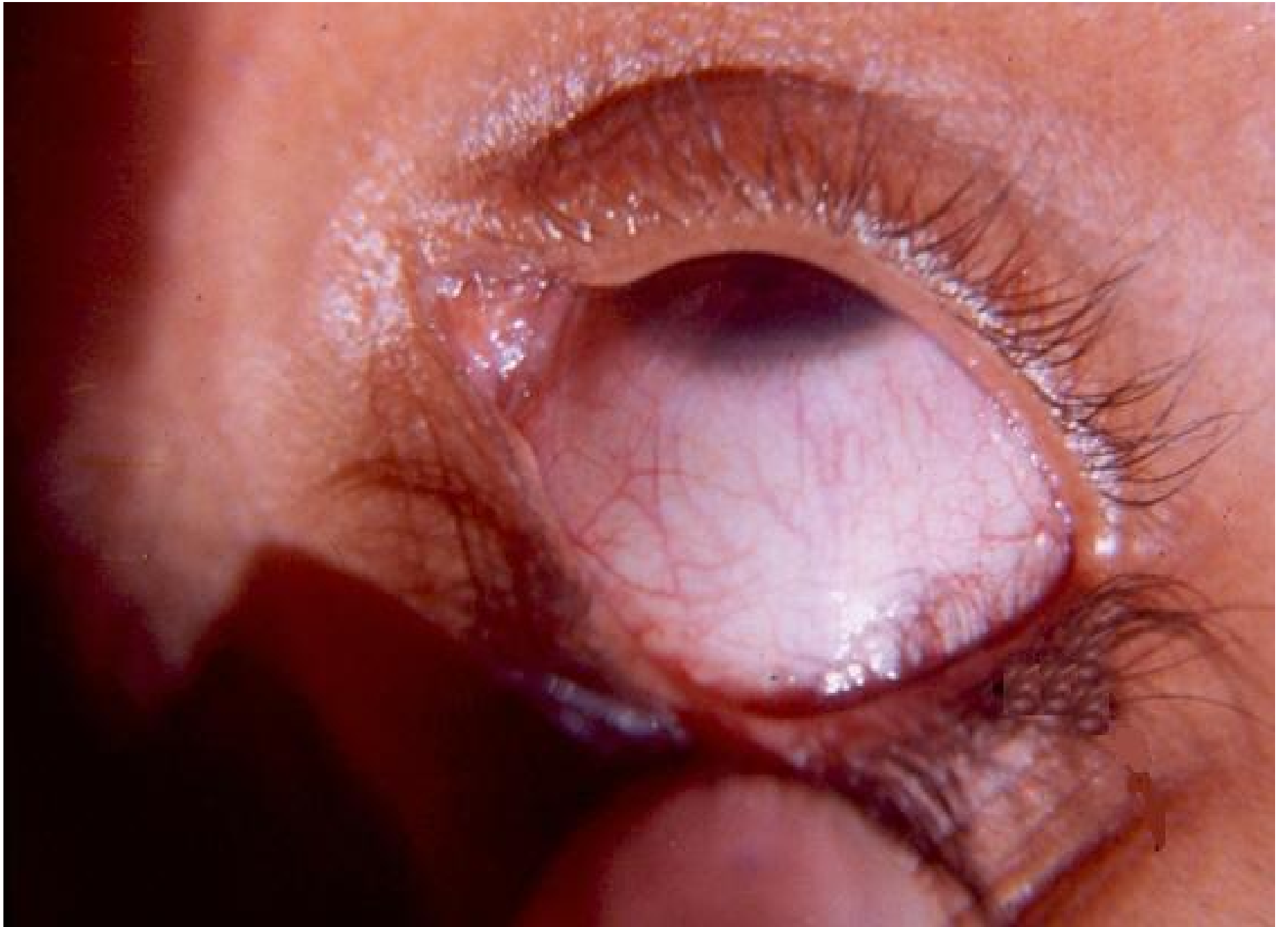- ⦿ **DOLOR**
- ⦿ **LAGRIMEO**
- ⦿ **FOTOFOBIA**
- ⦿ **HALOS COLOREADOS**
- ⦿ **ARDOR - PICAZÓN**

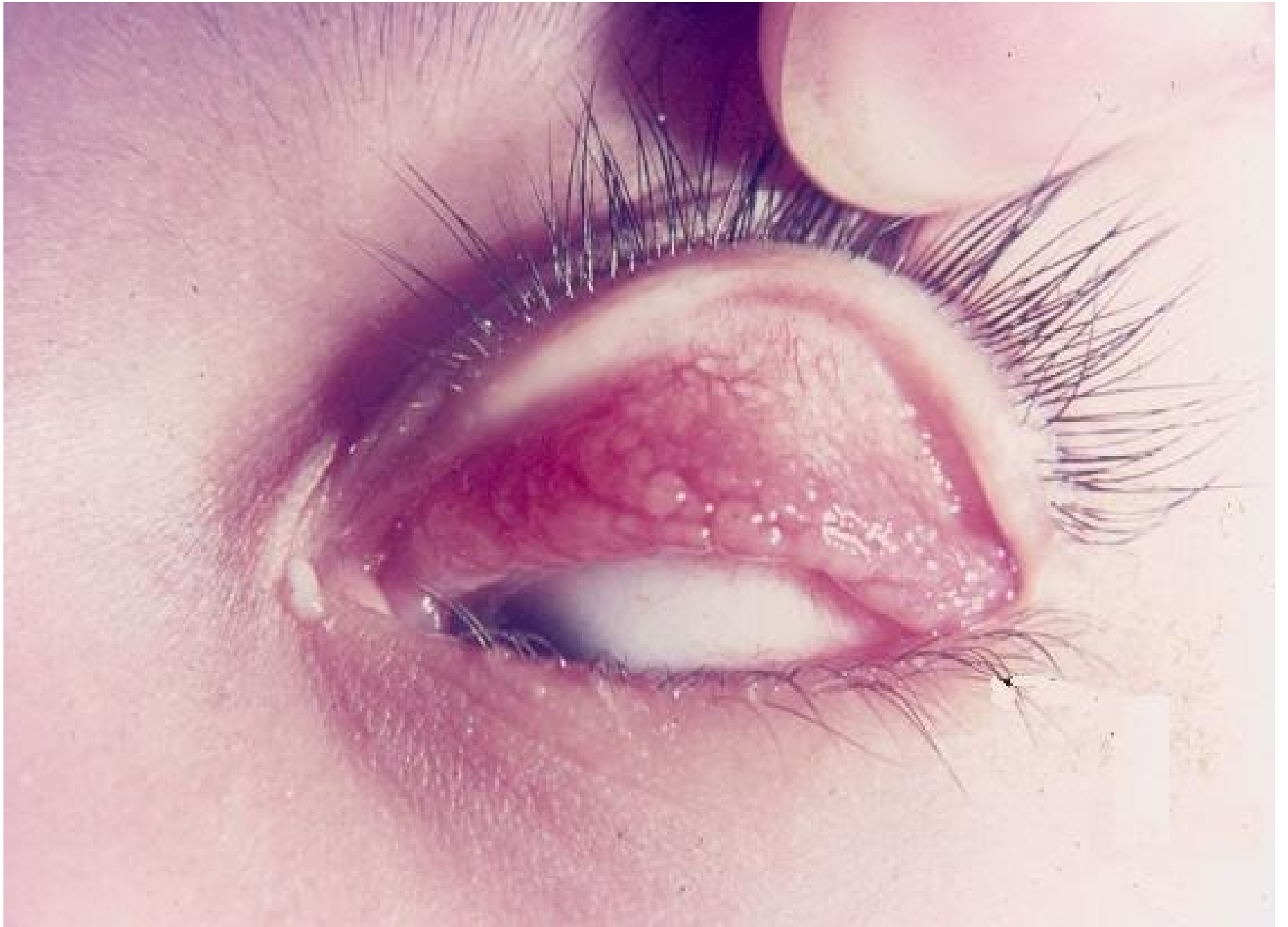


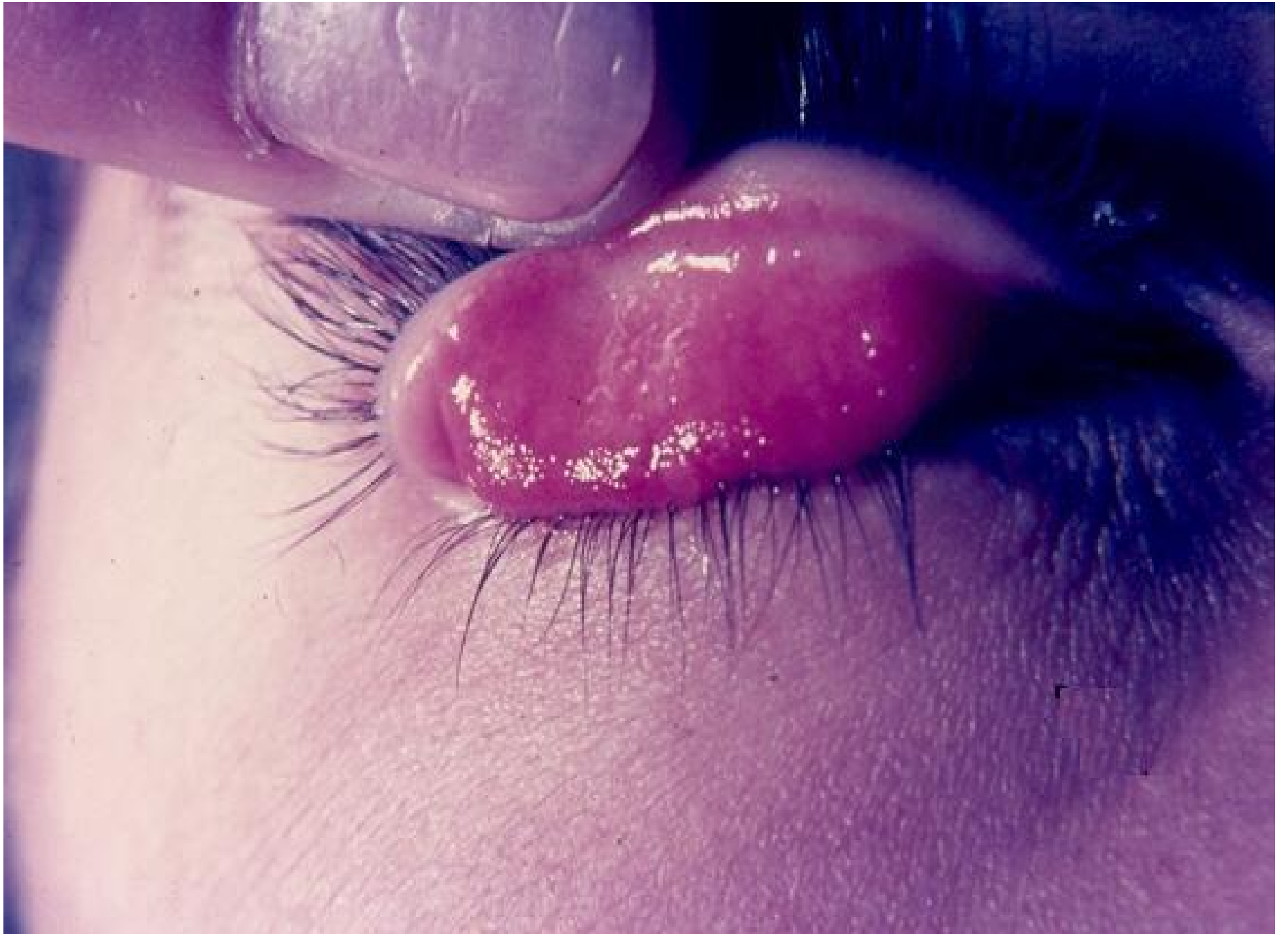


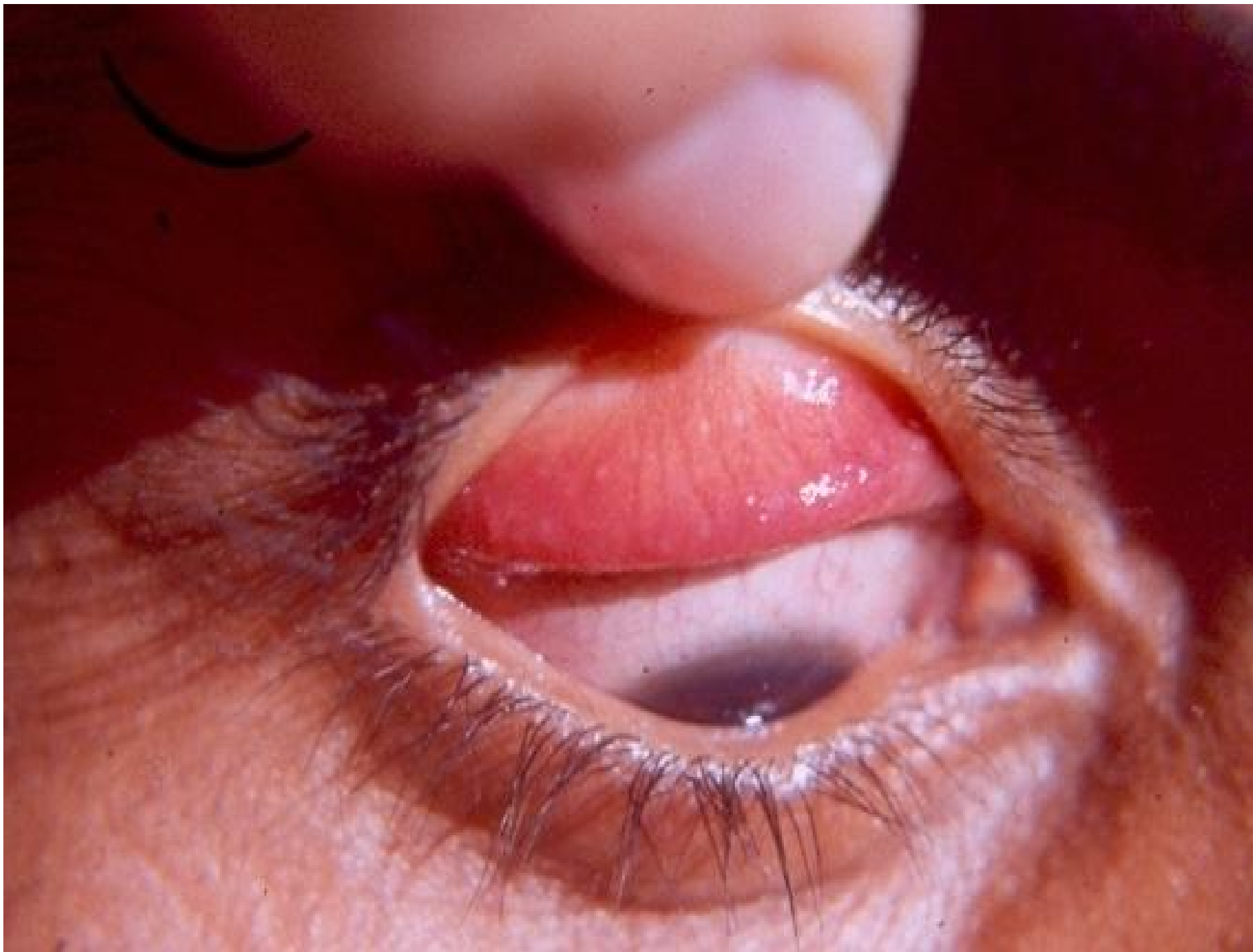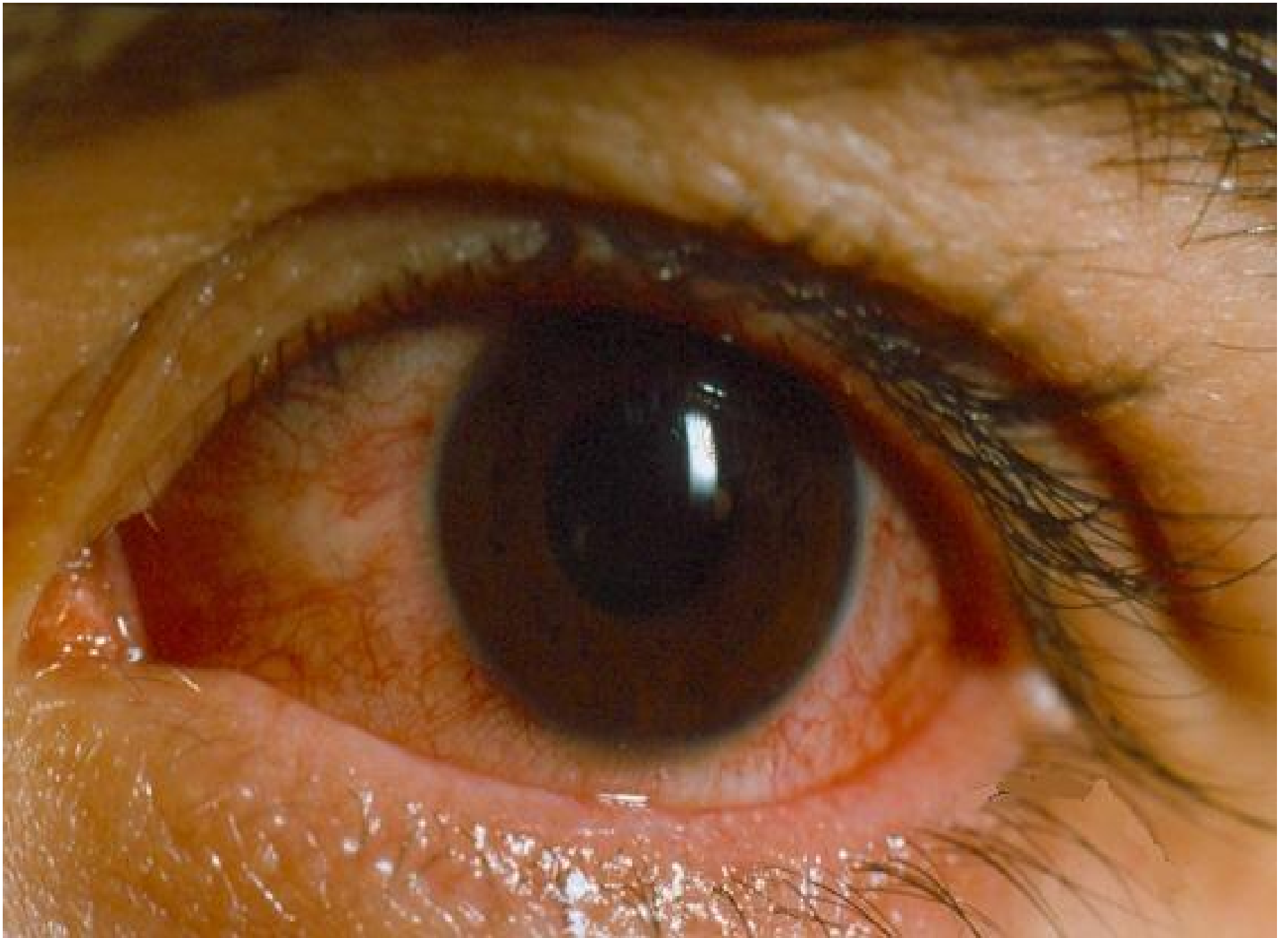




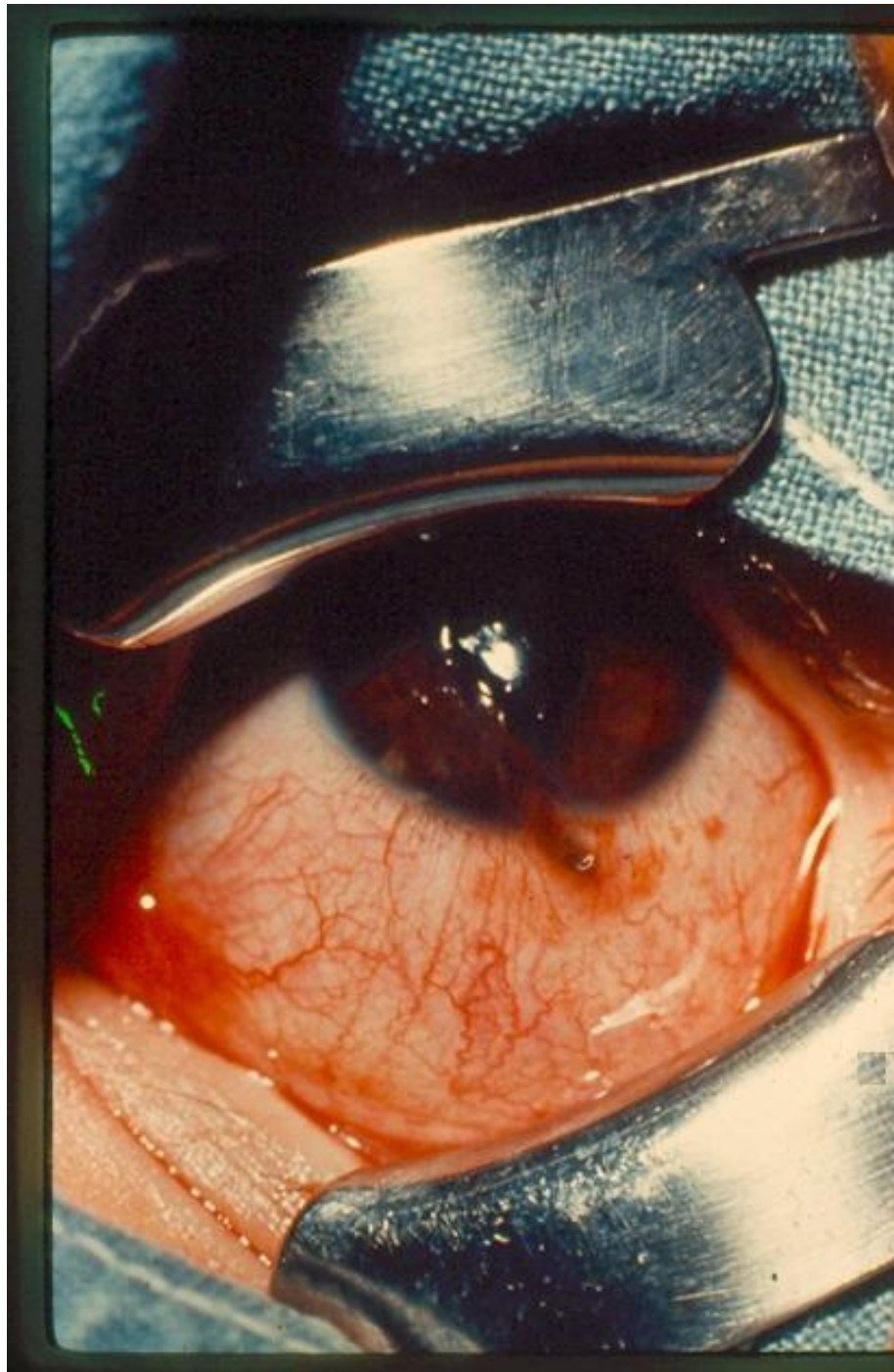





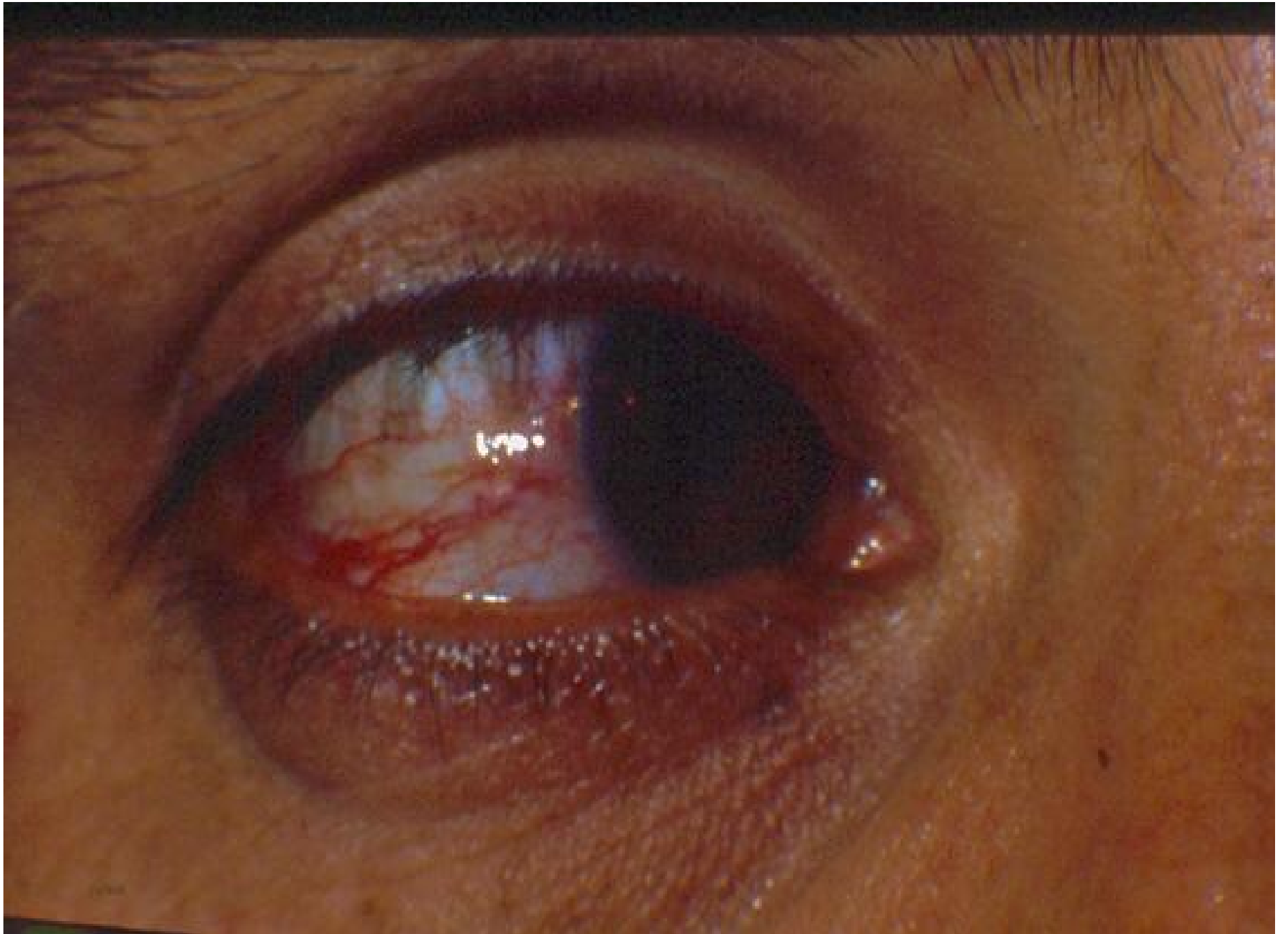


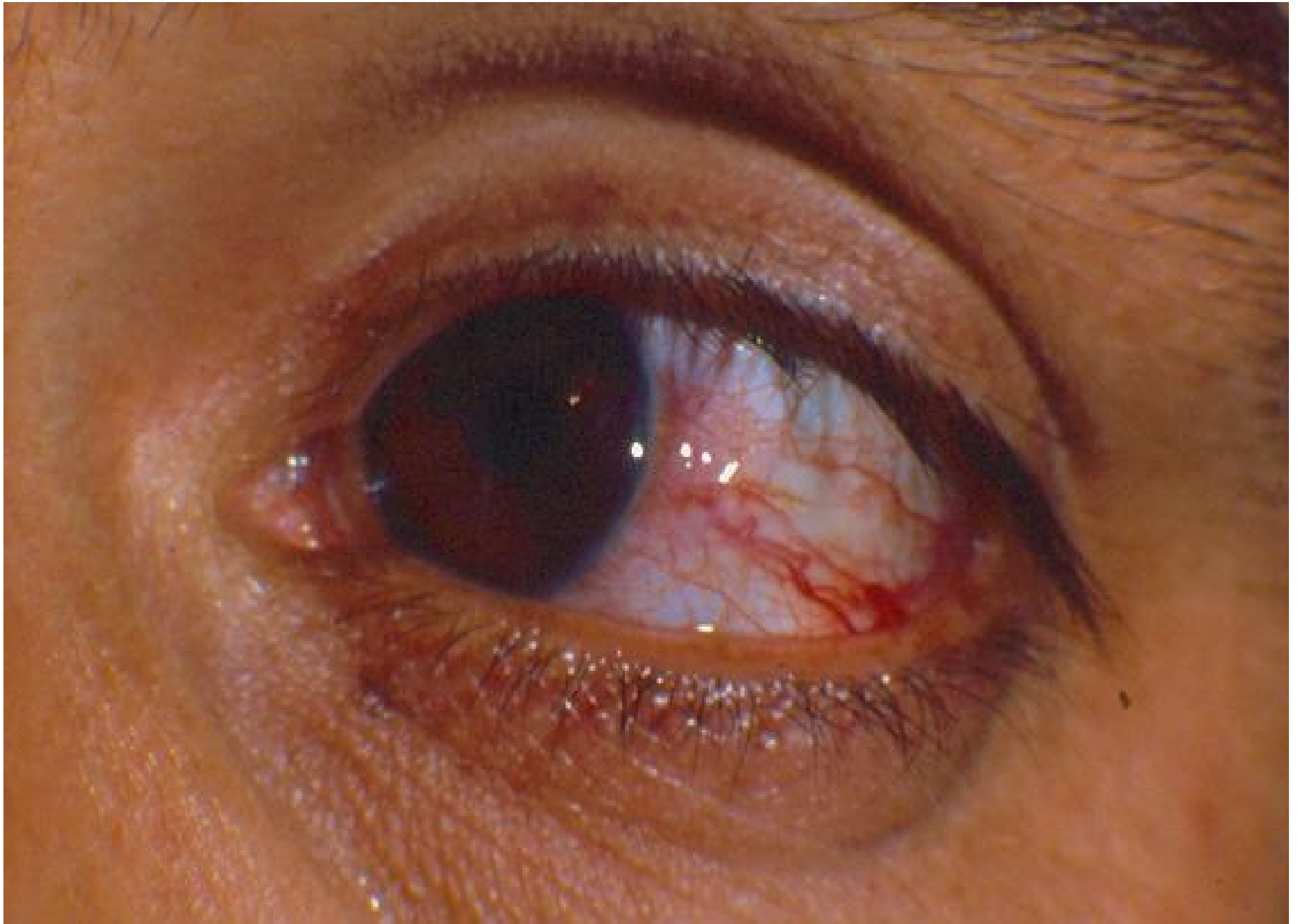


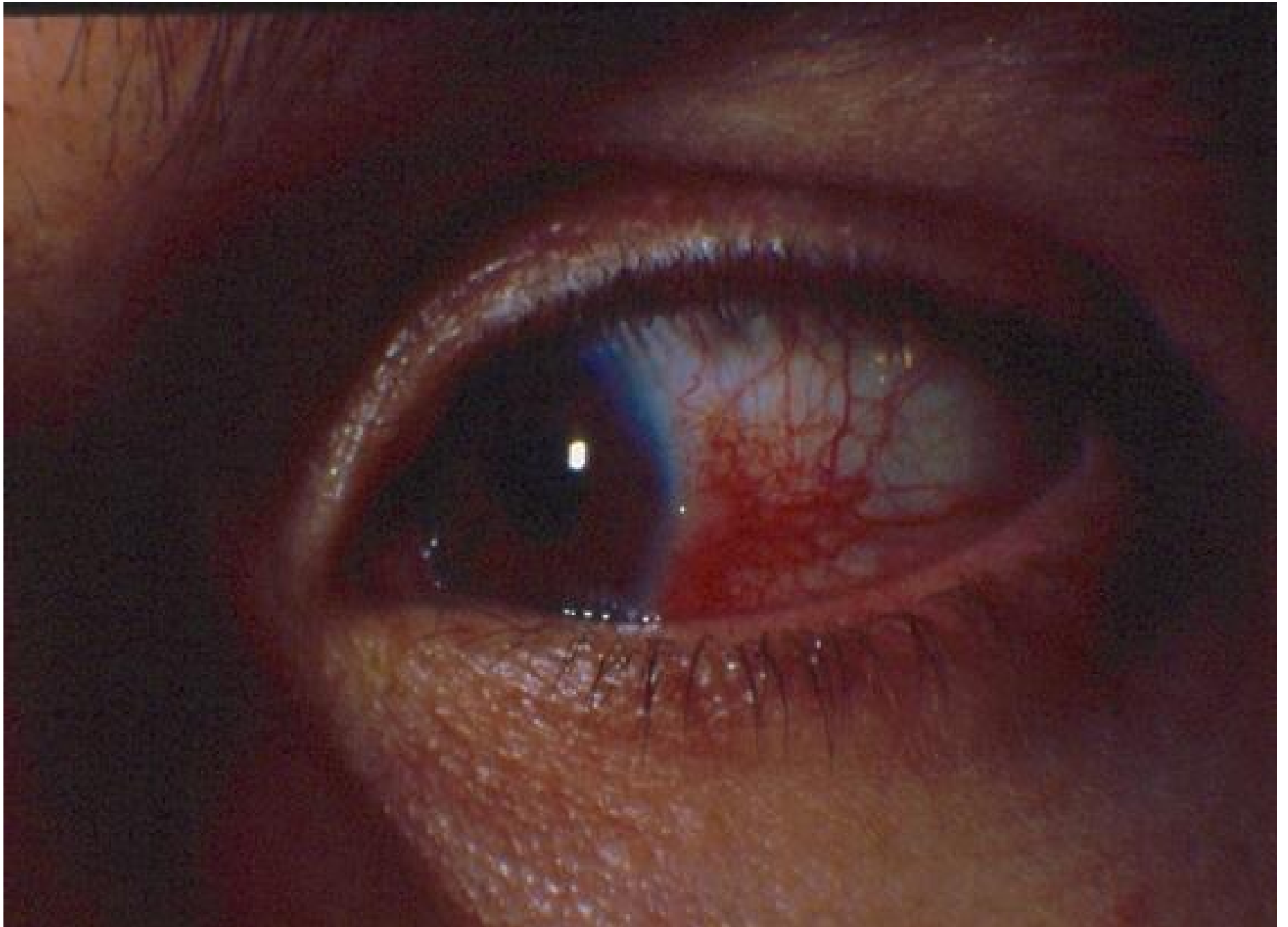
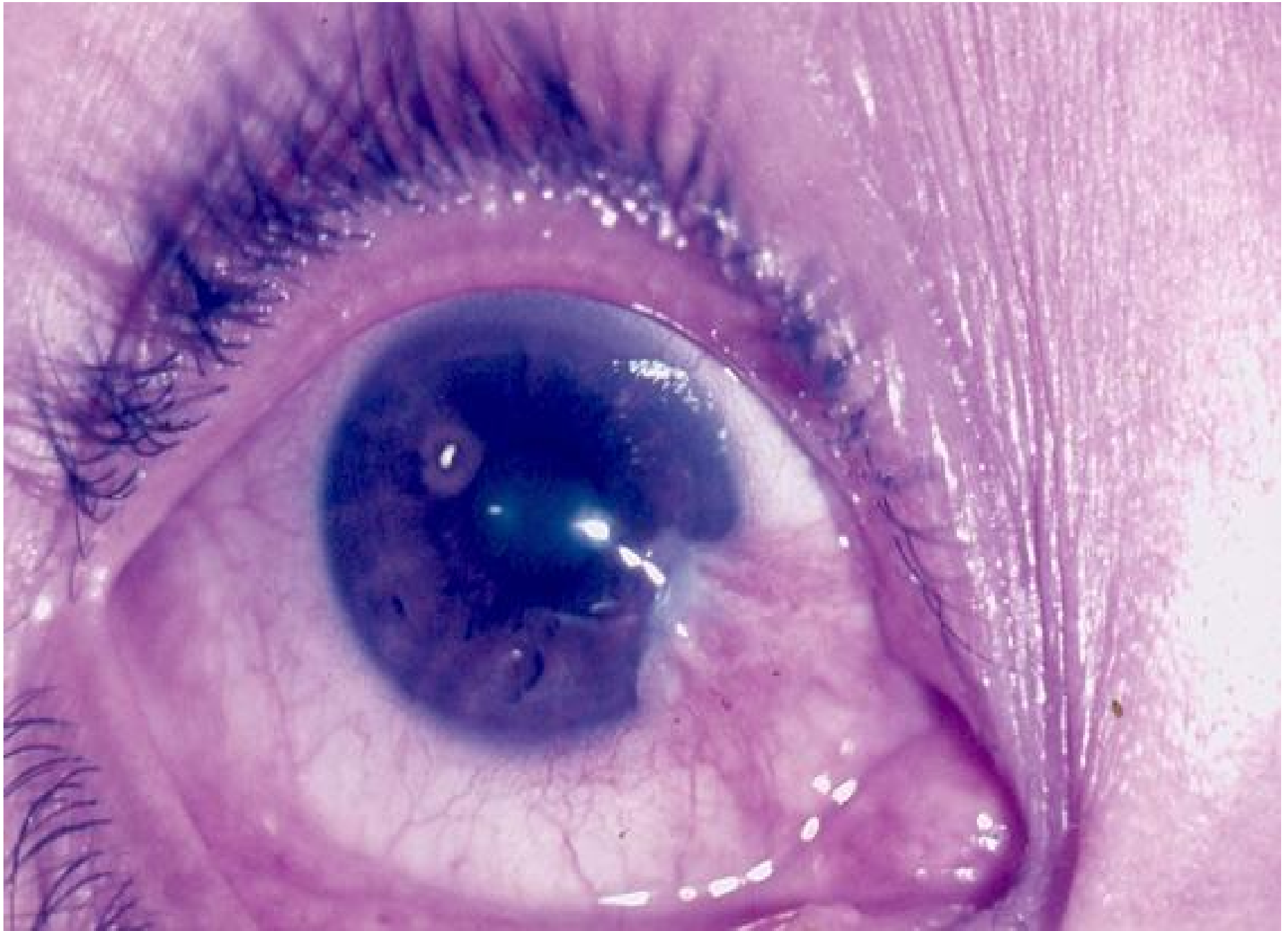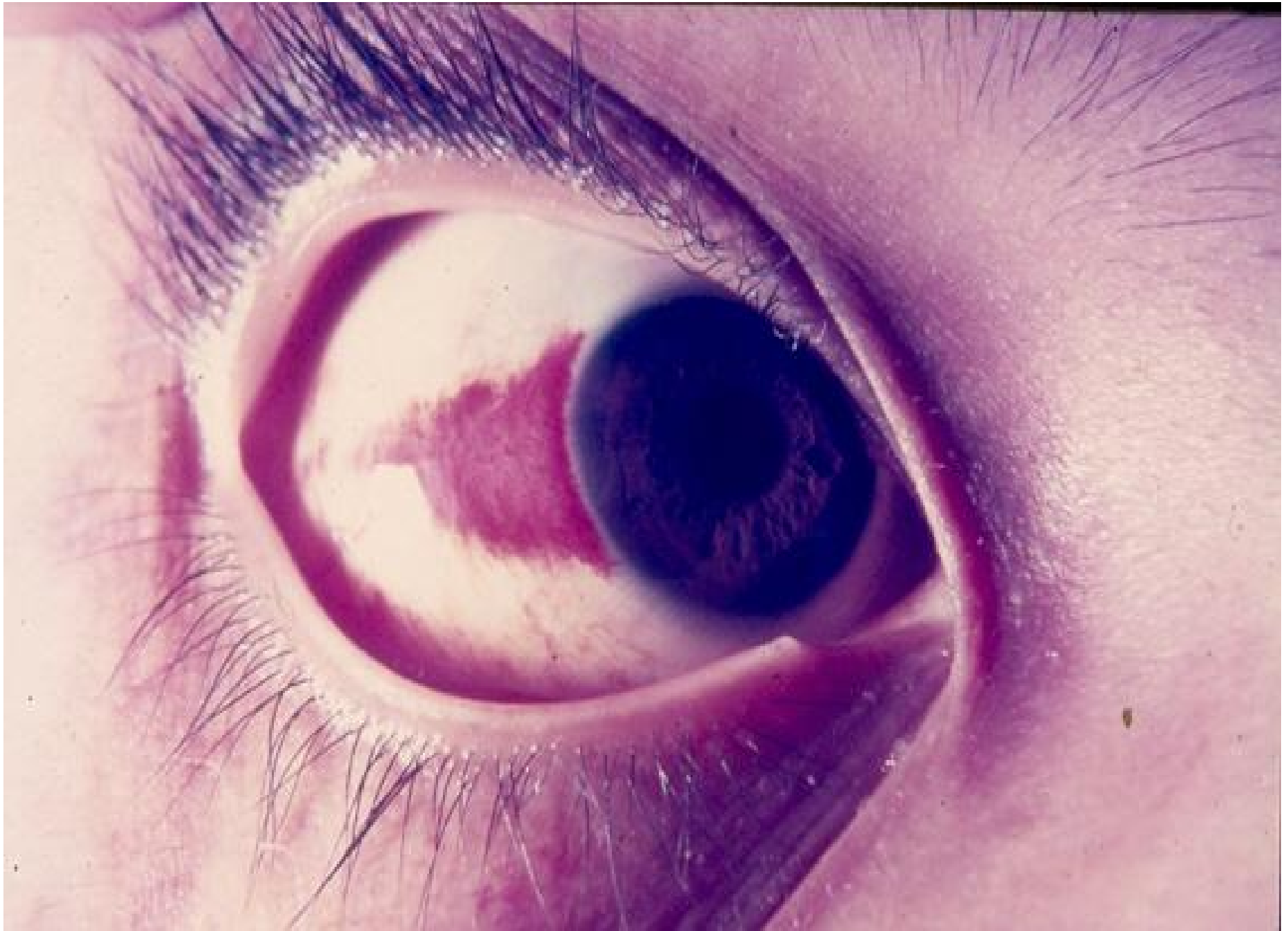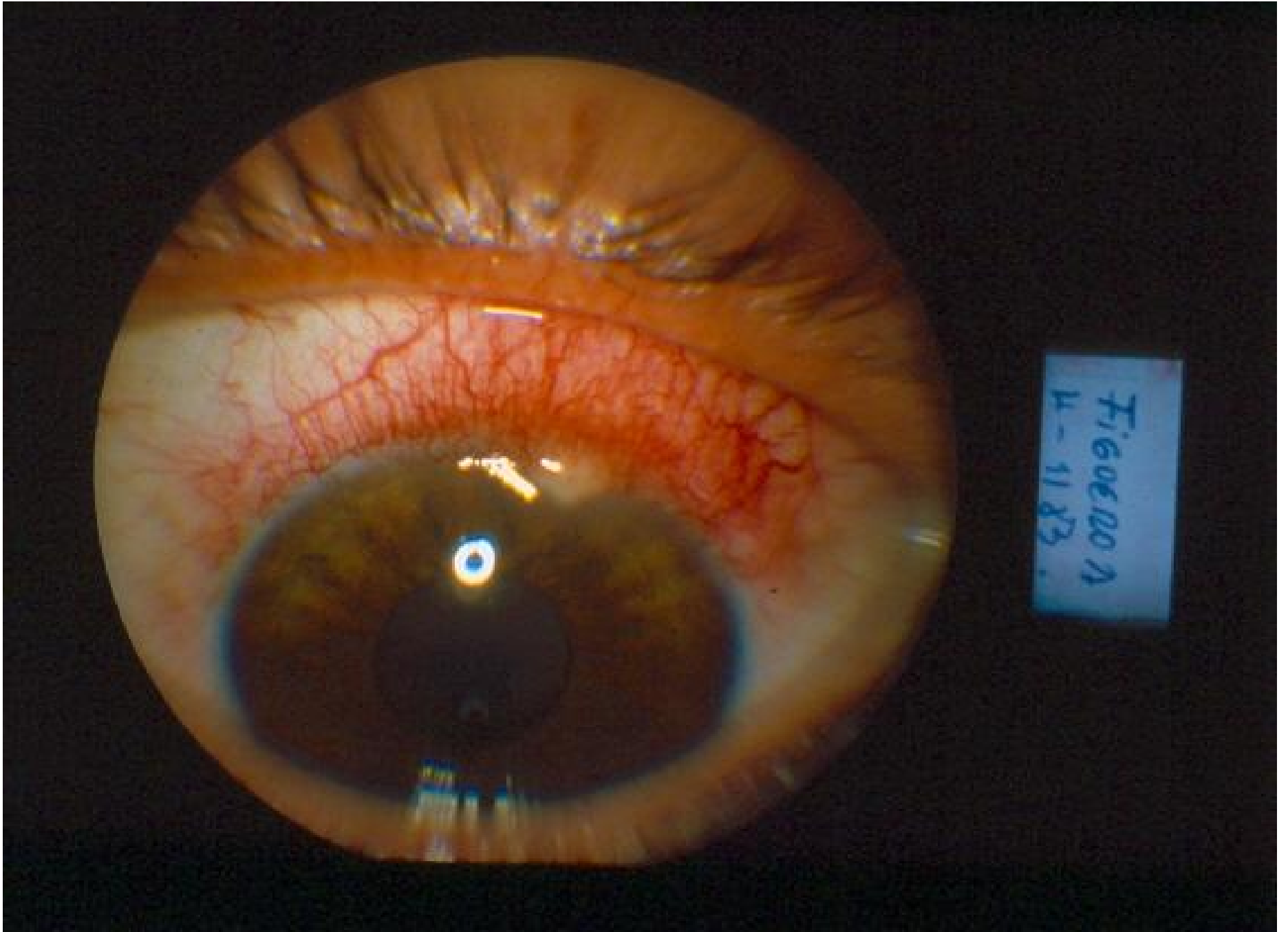




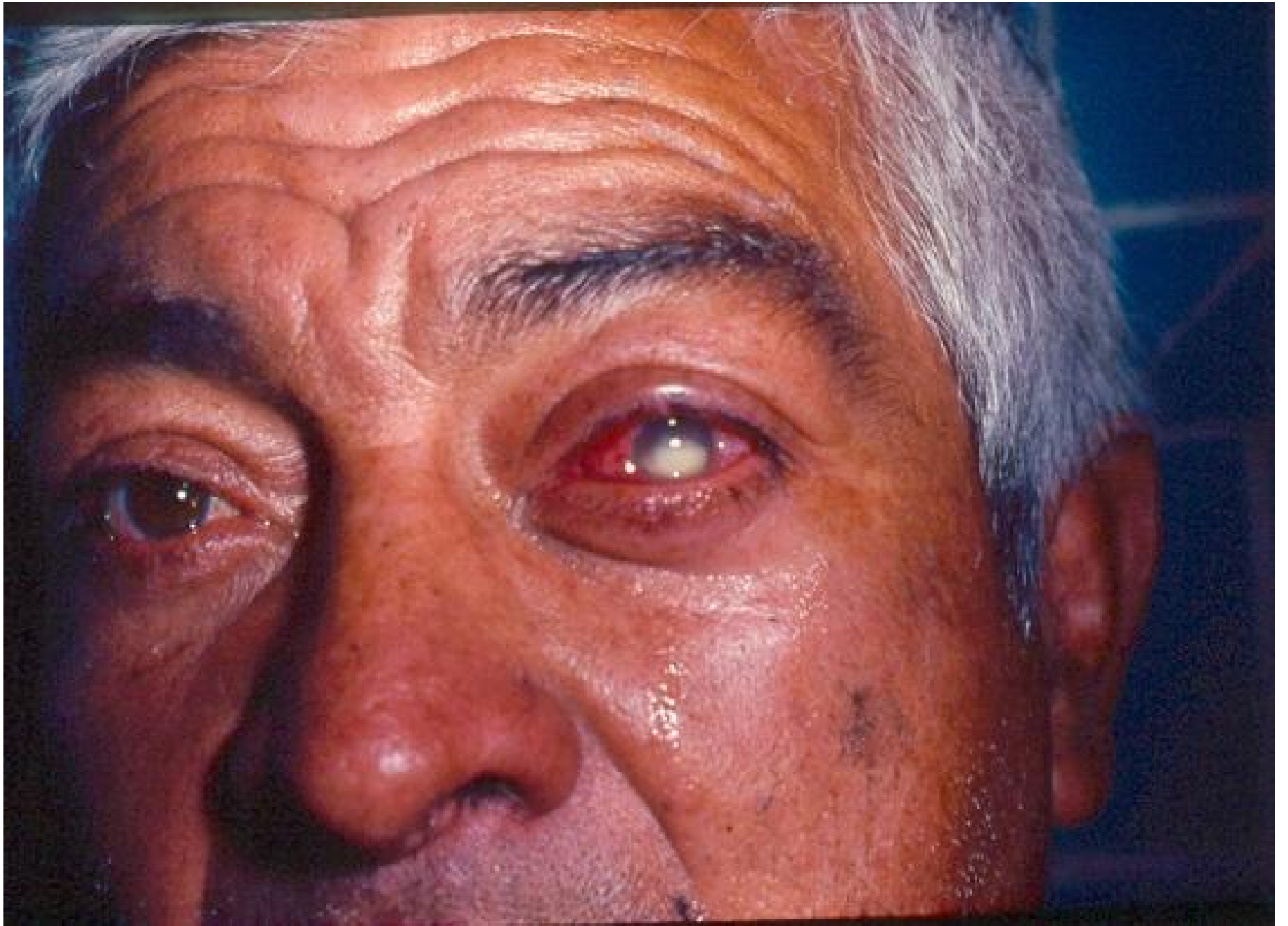








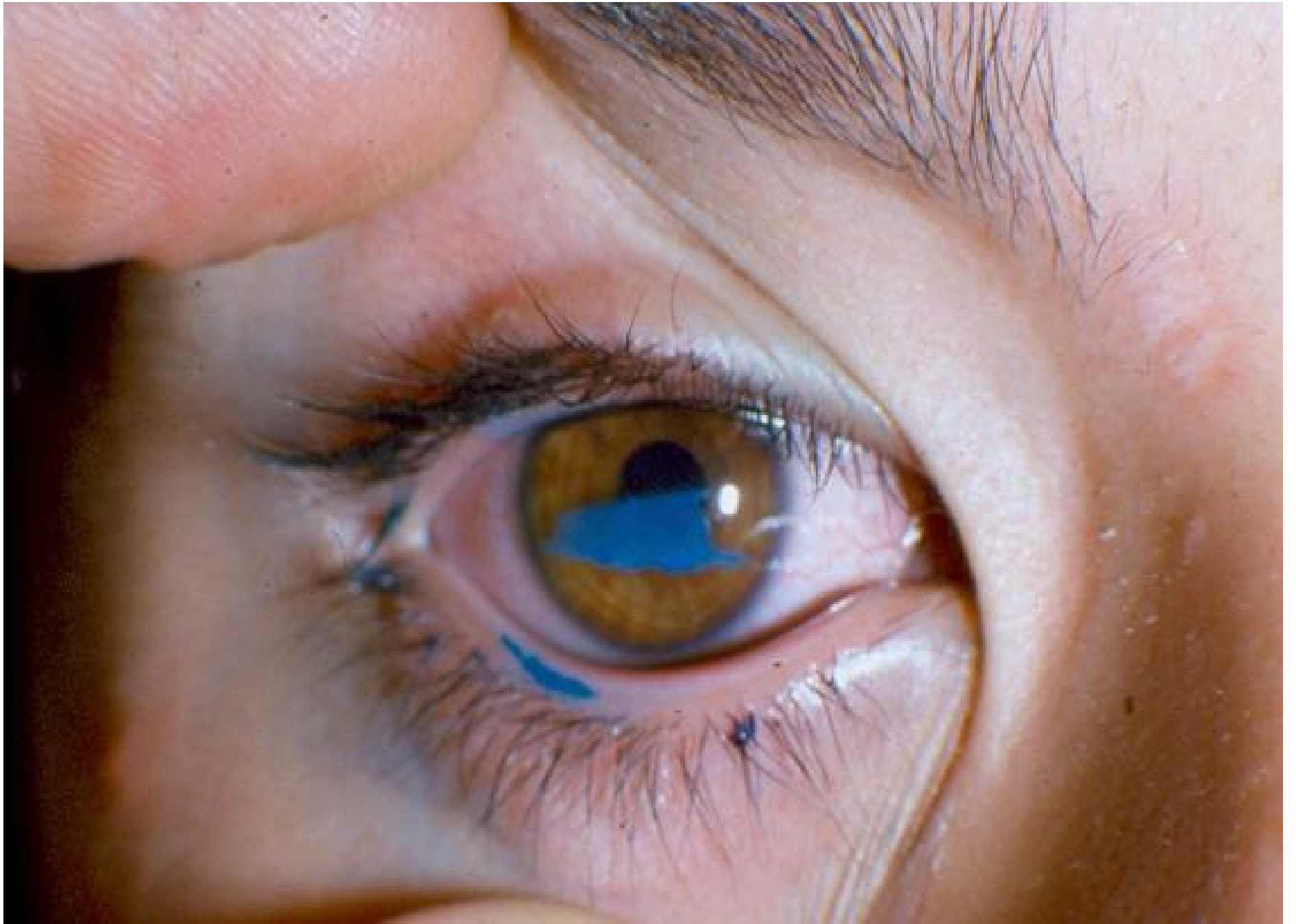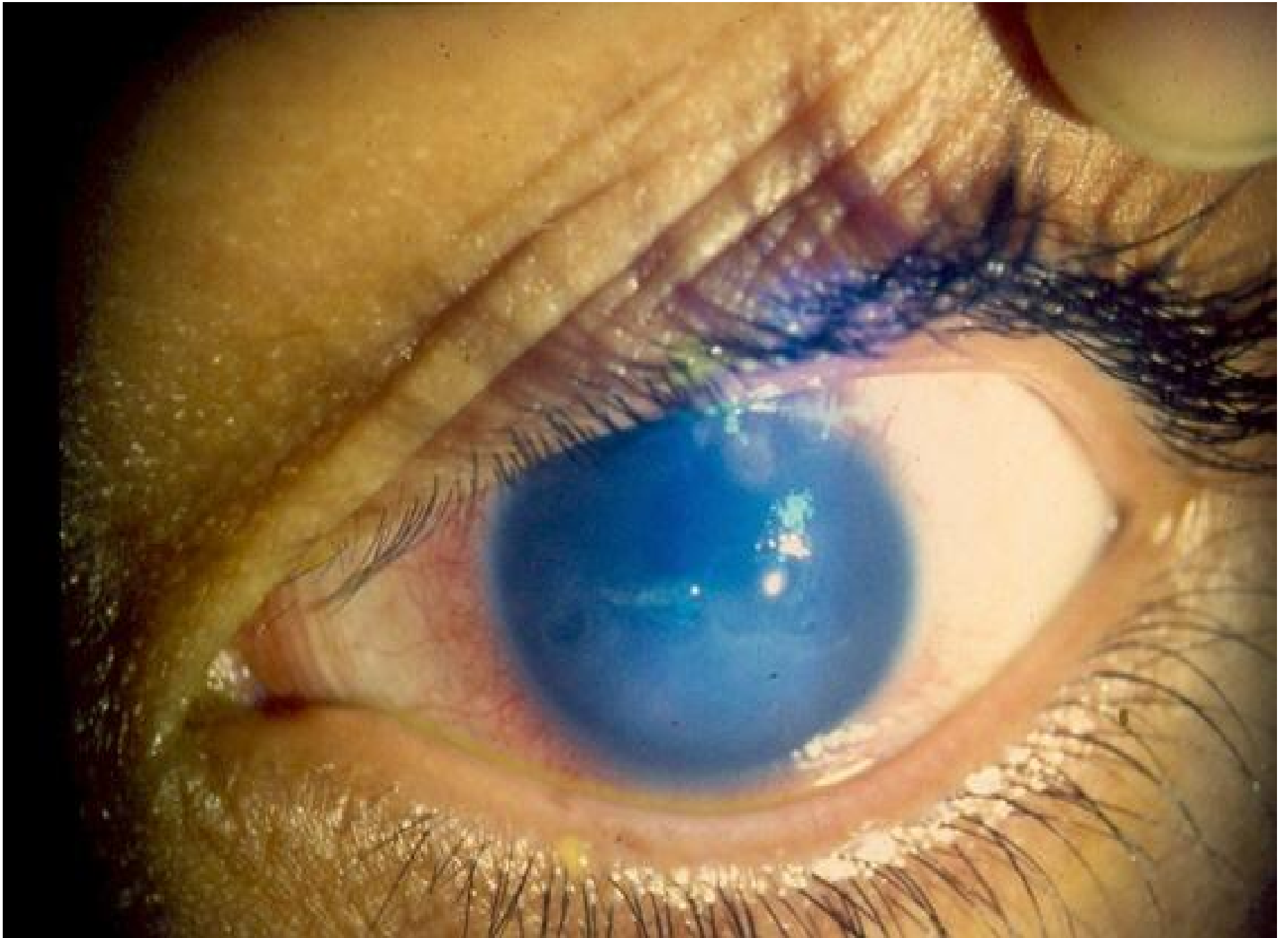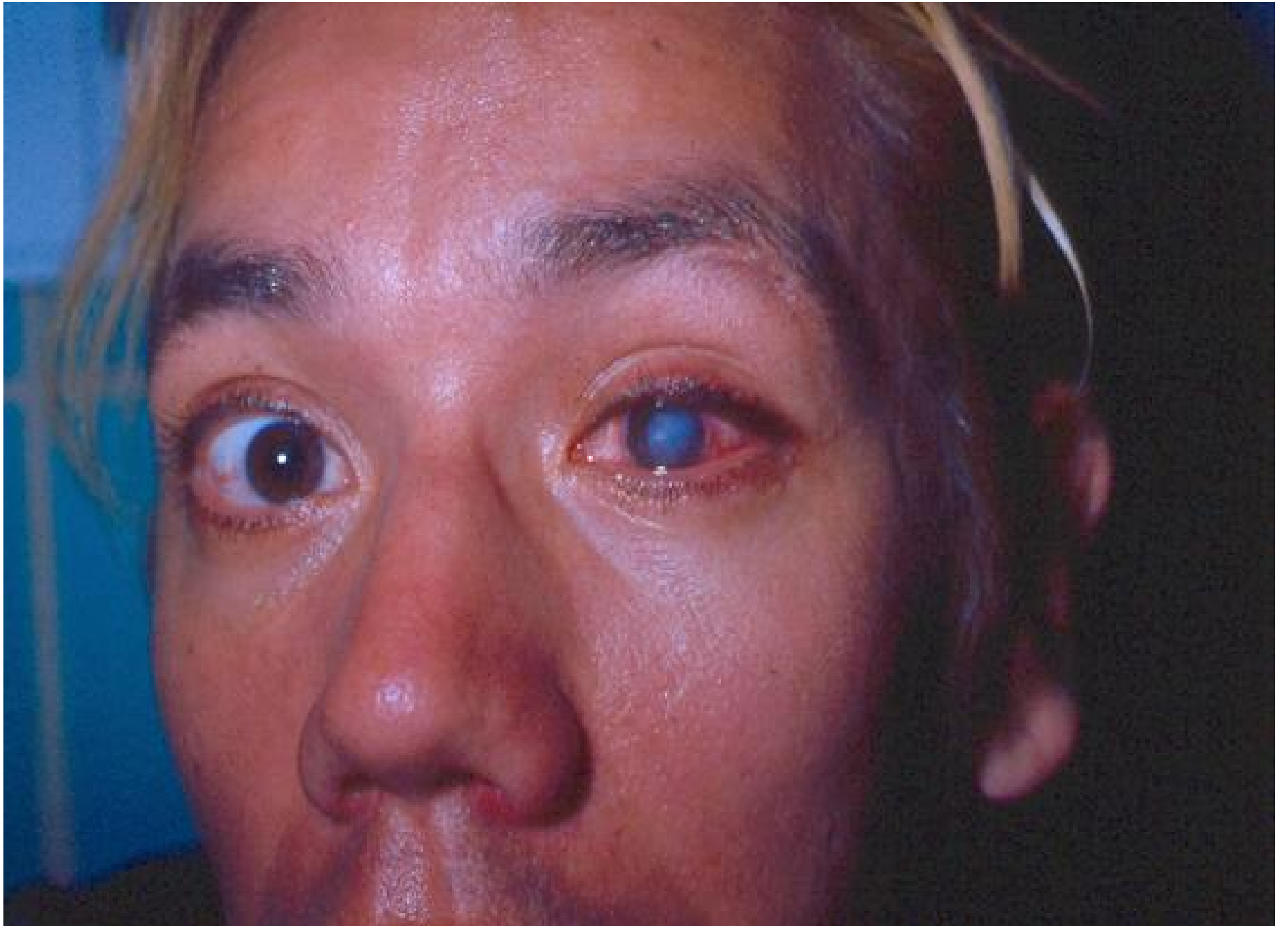FIGUEROA  
U-1183

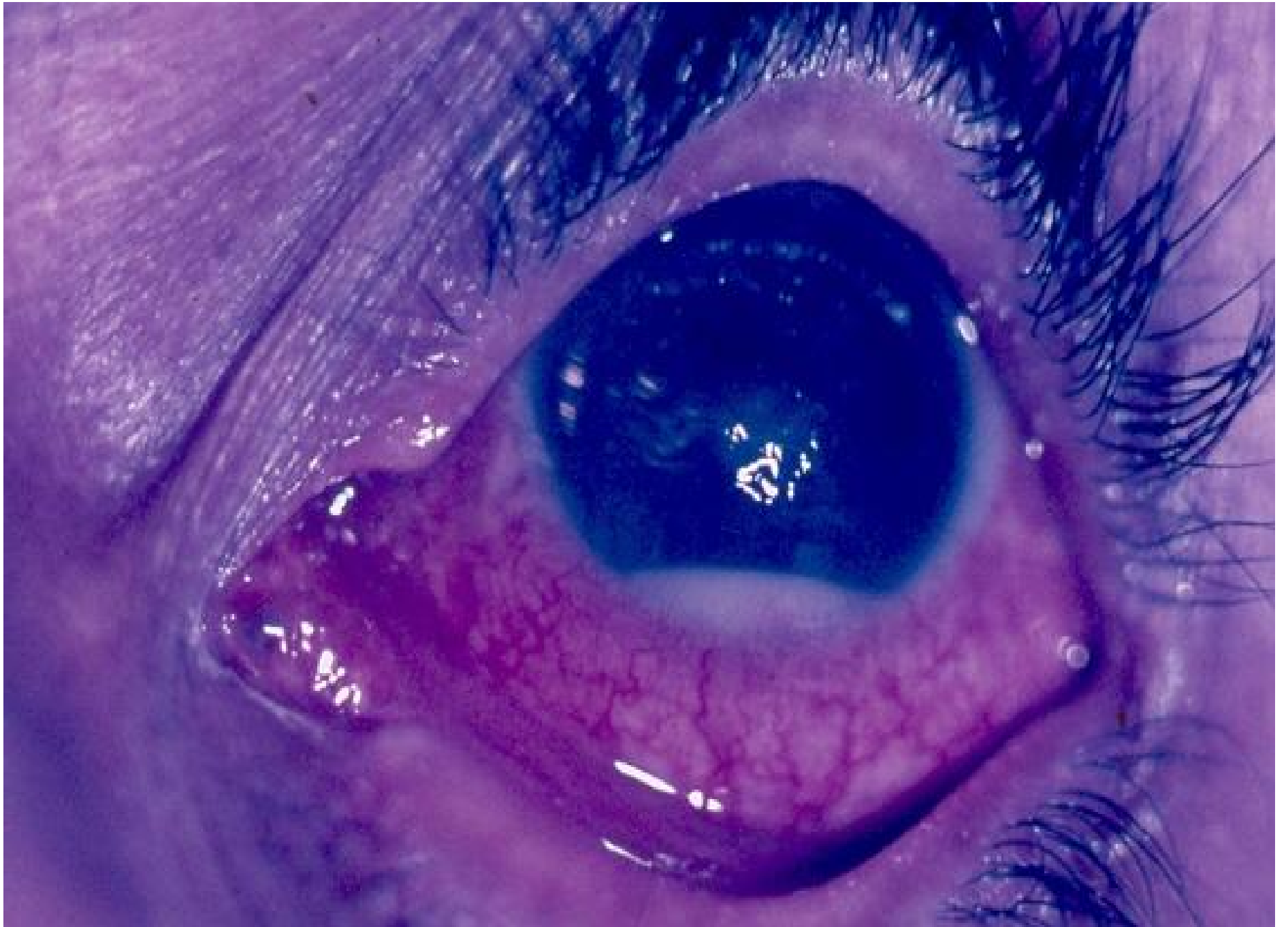


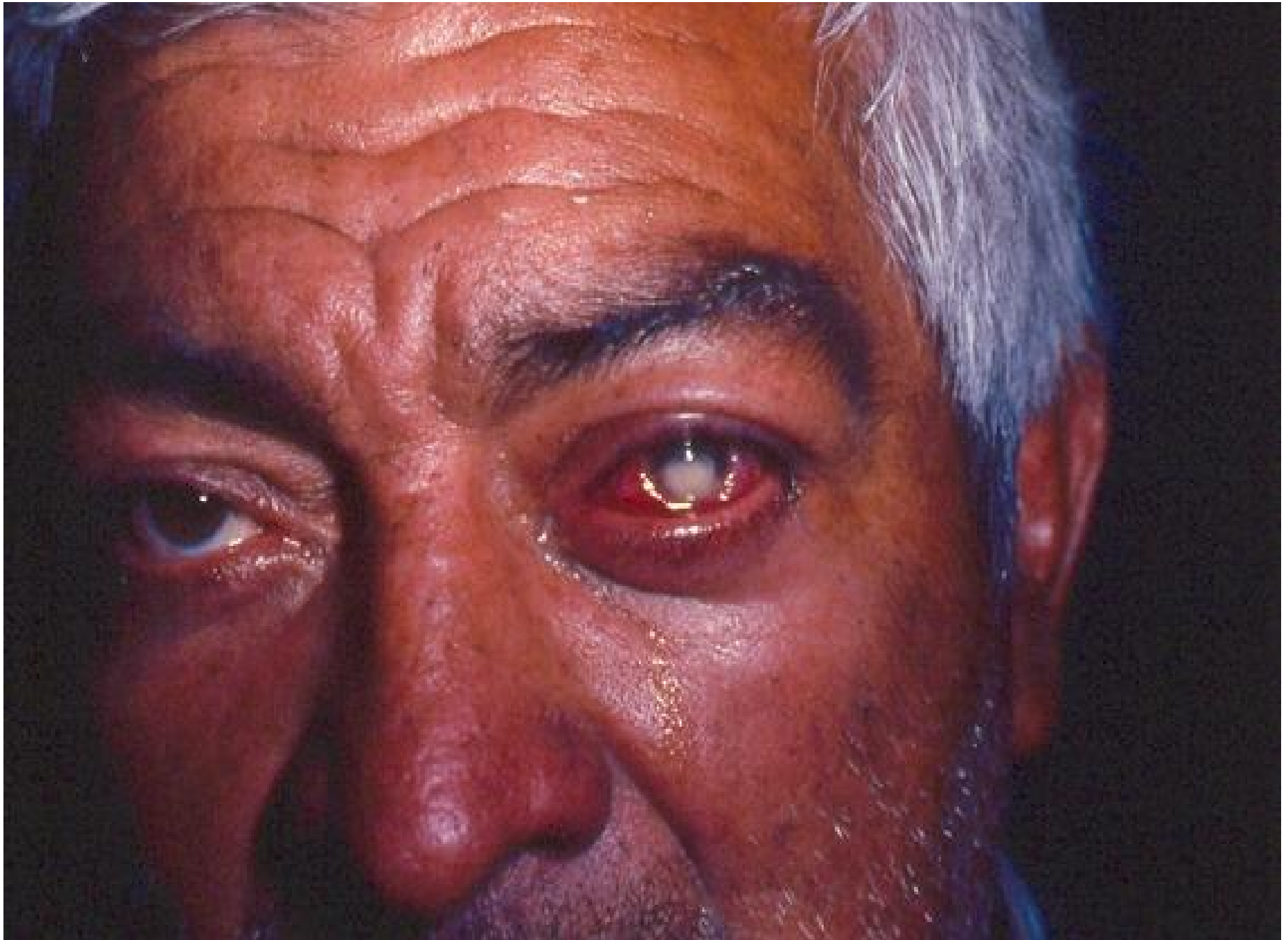

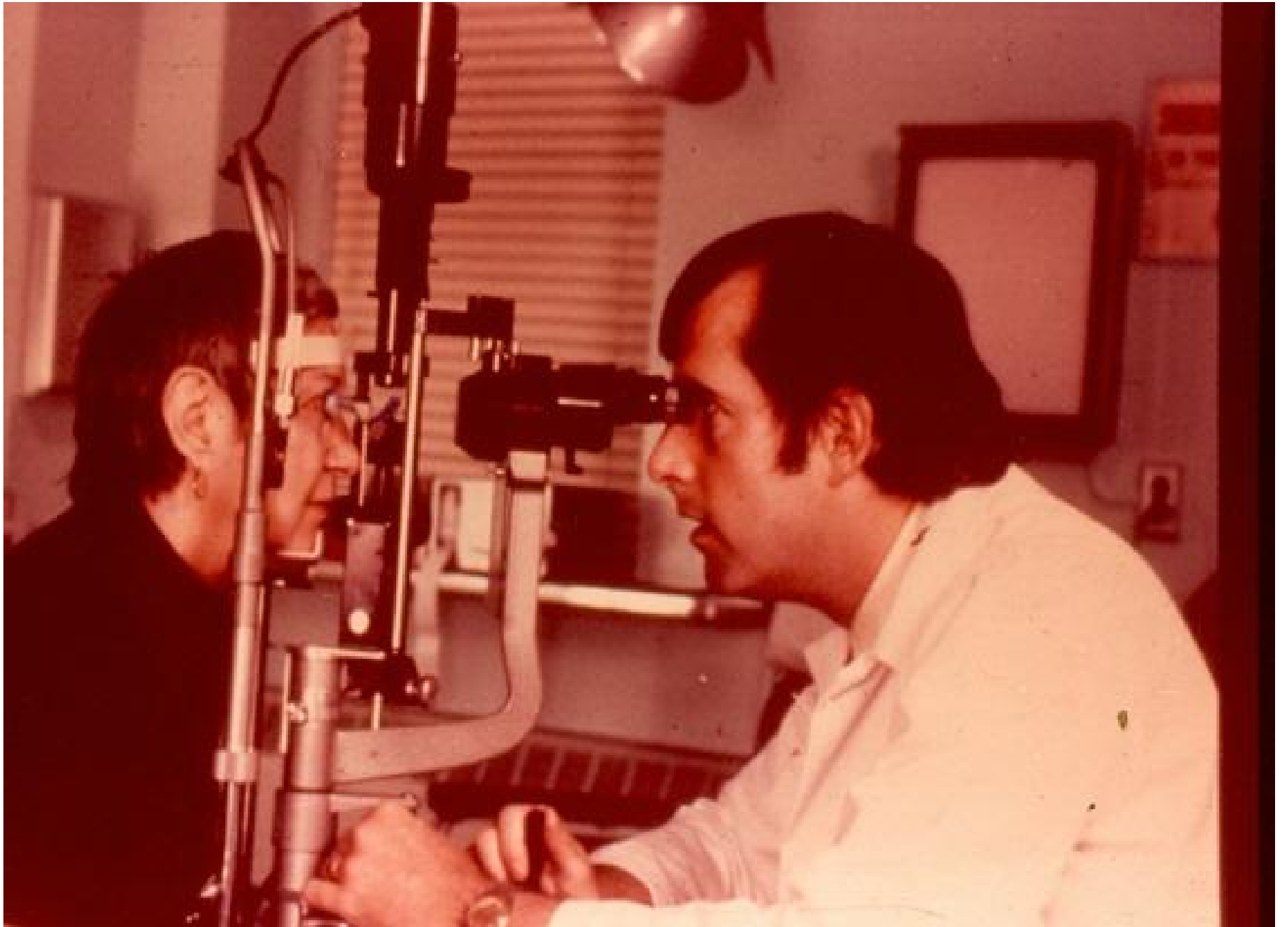



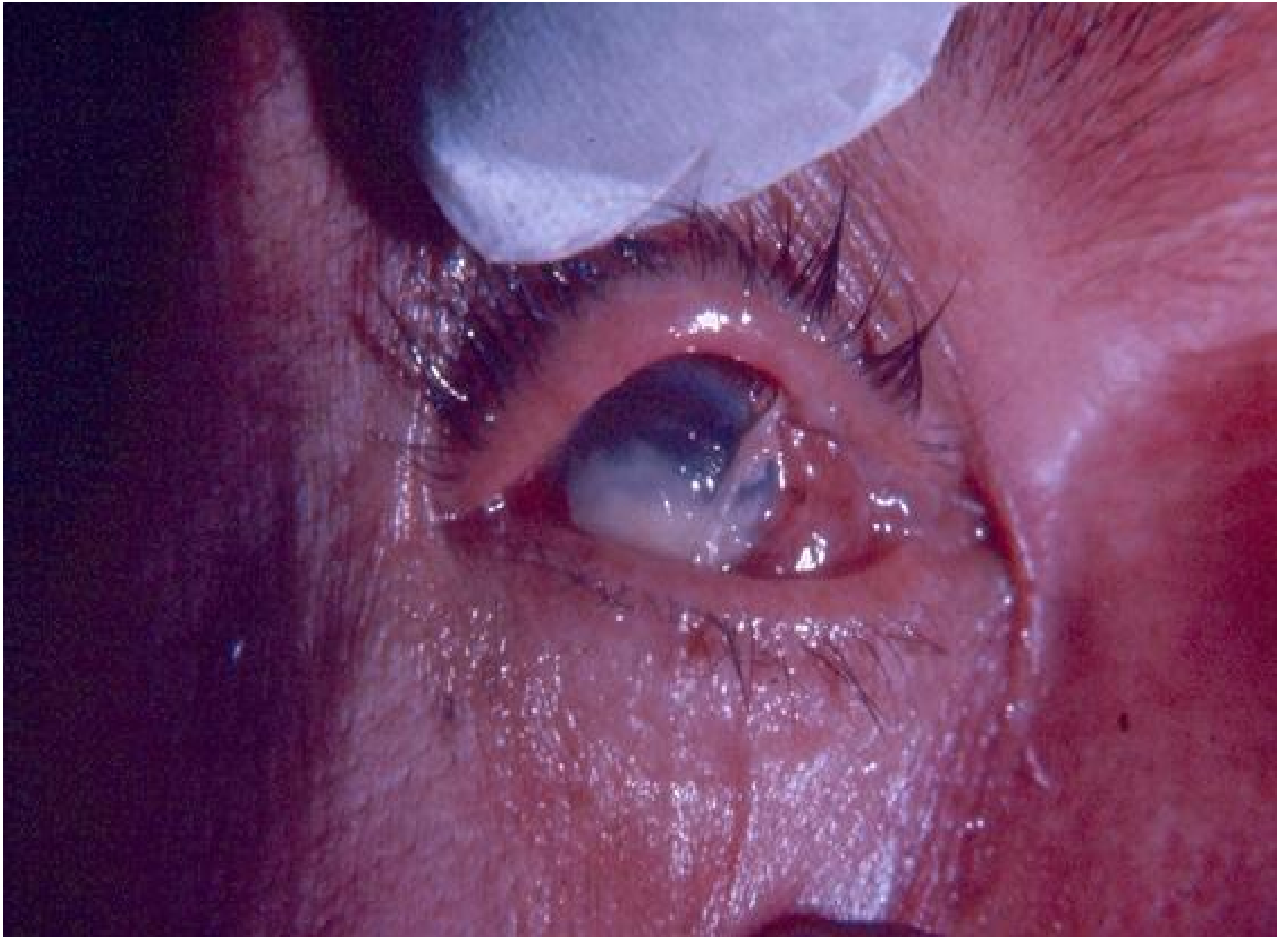


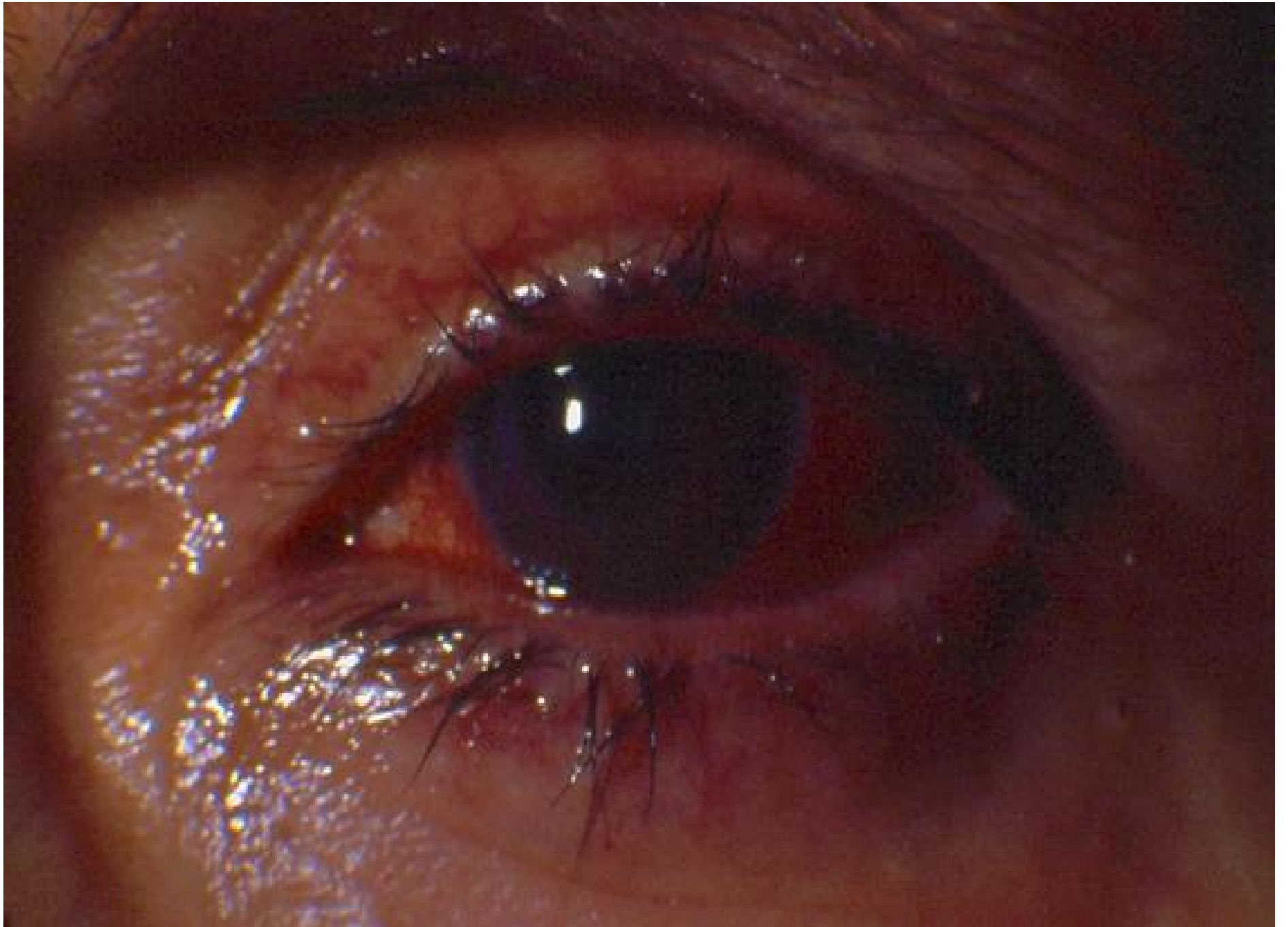




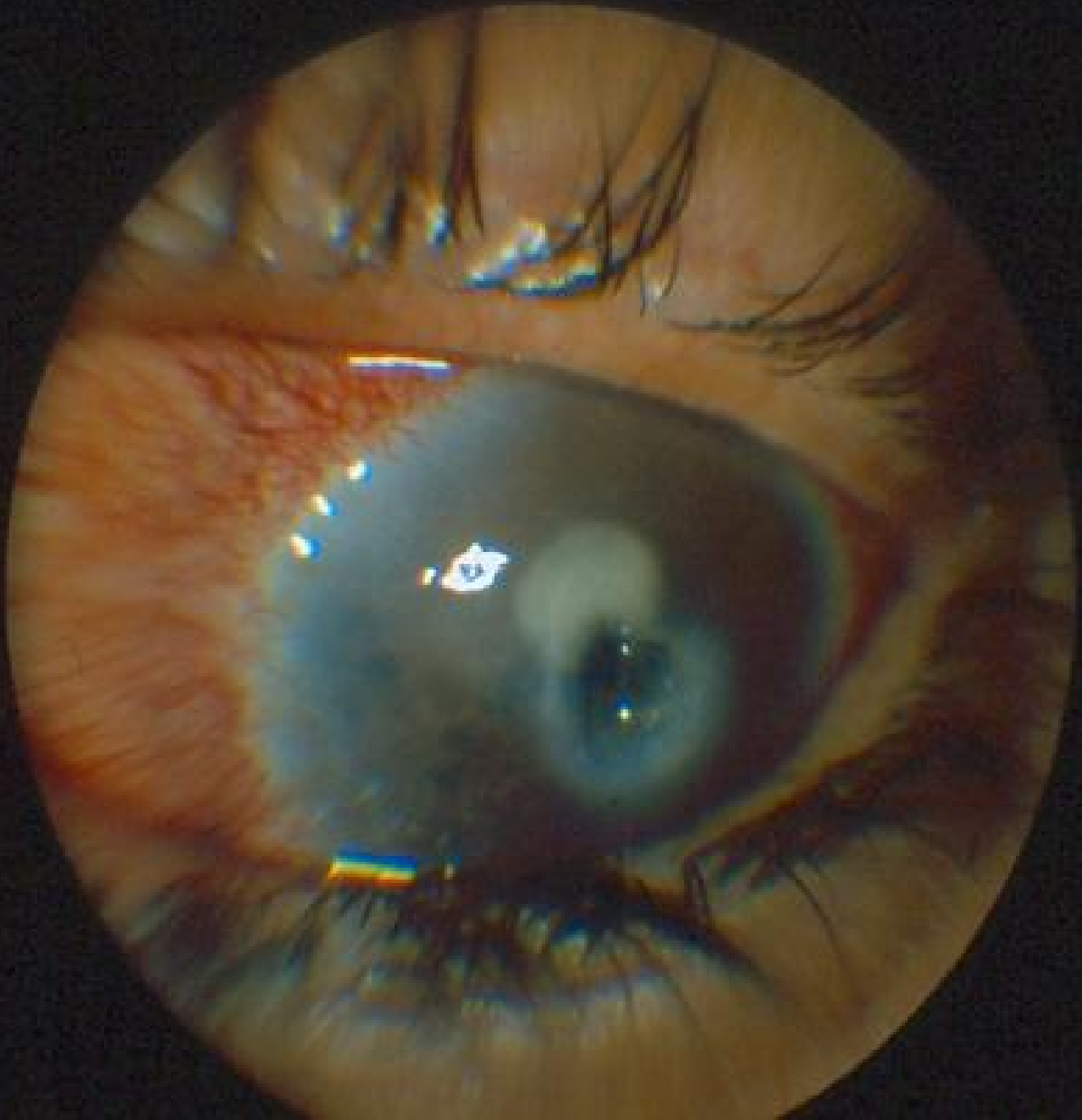
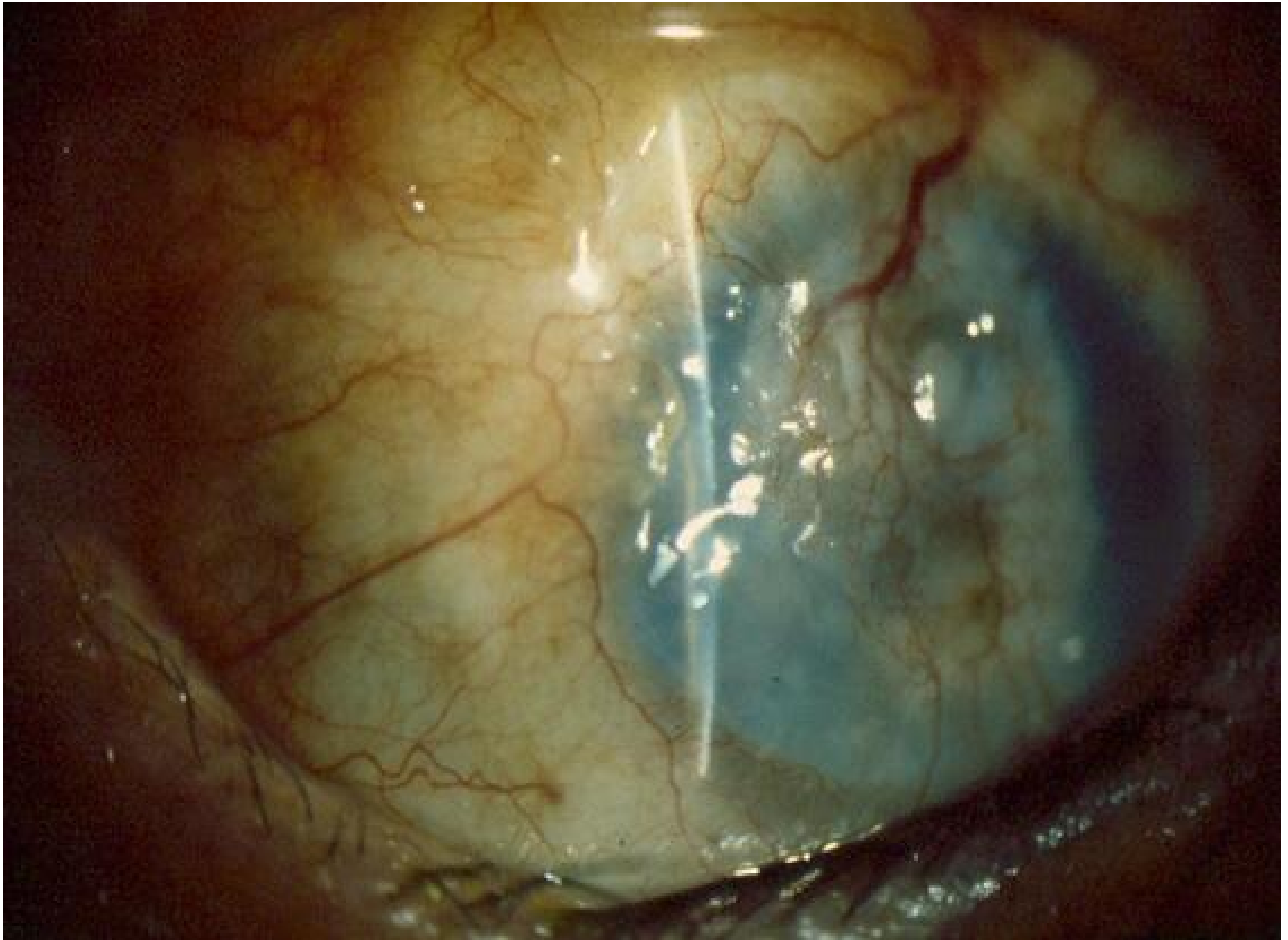








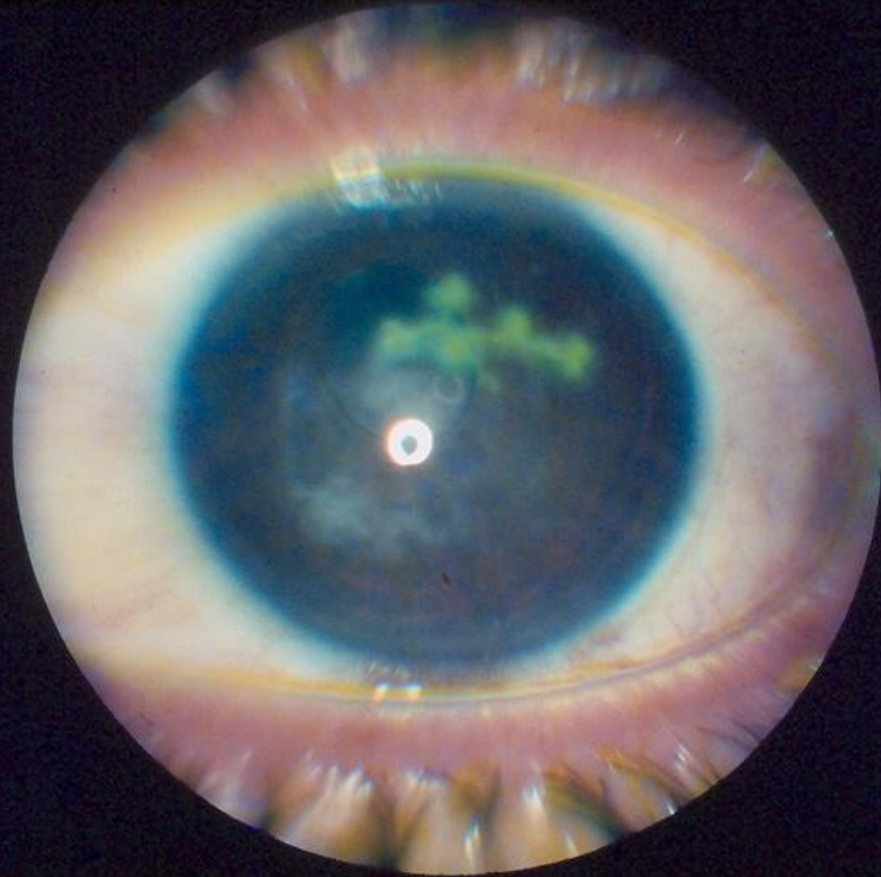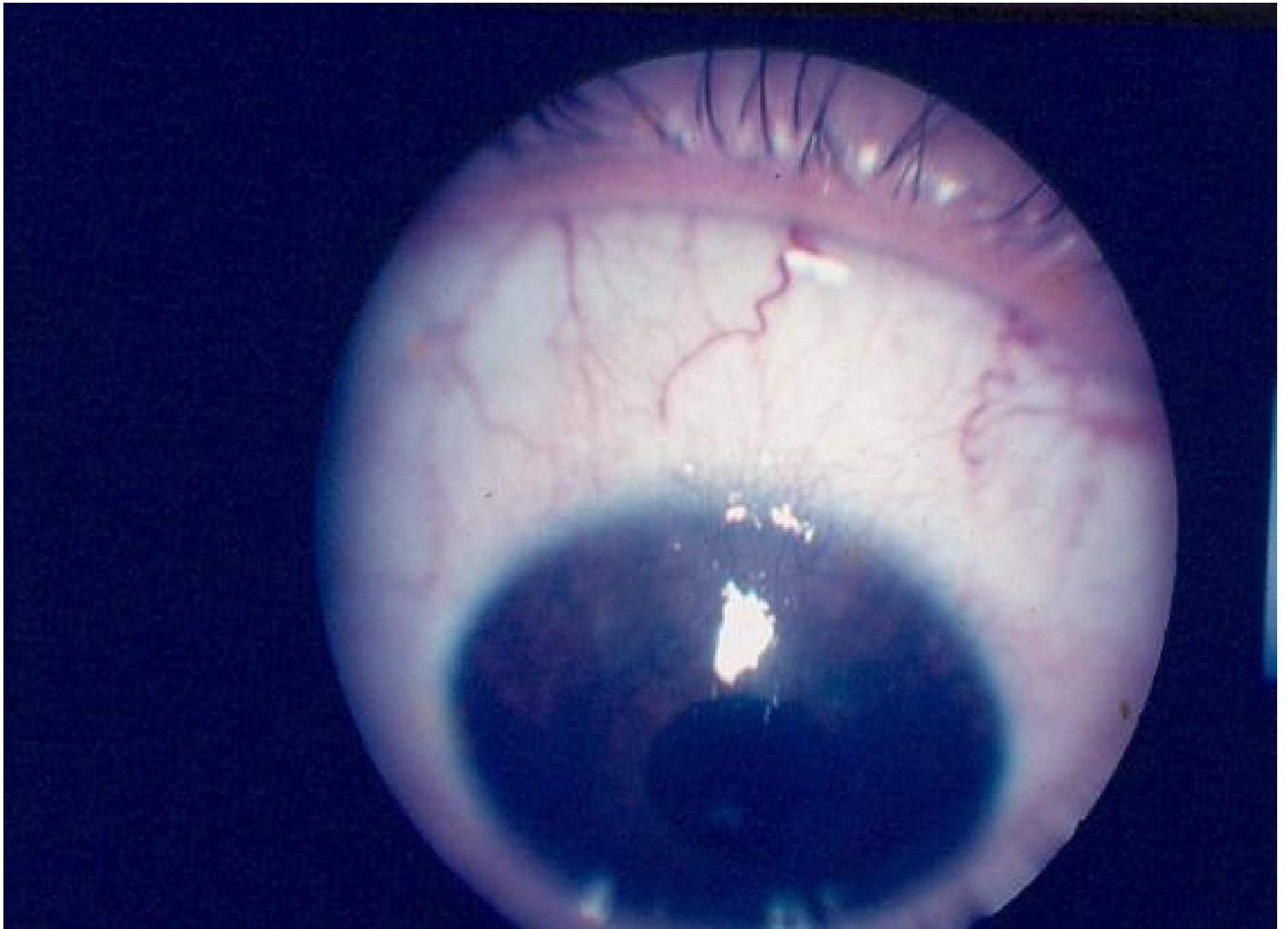
see id 257  
Choroid

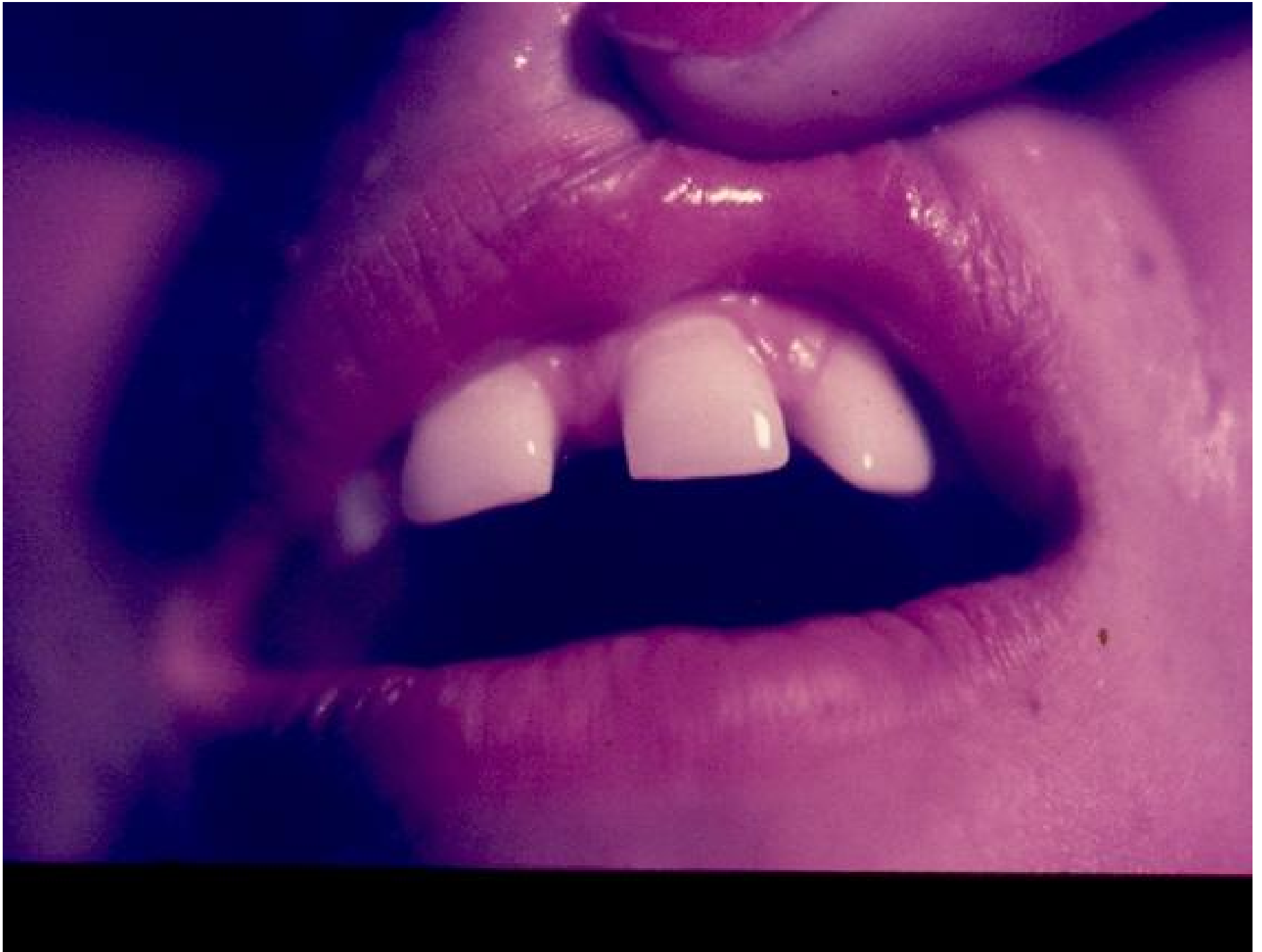

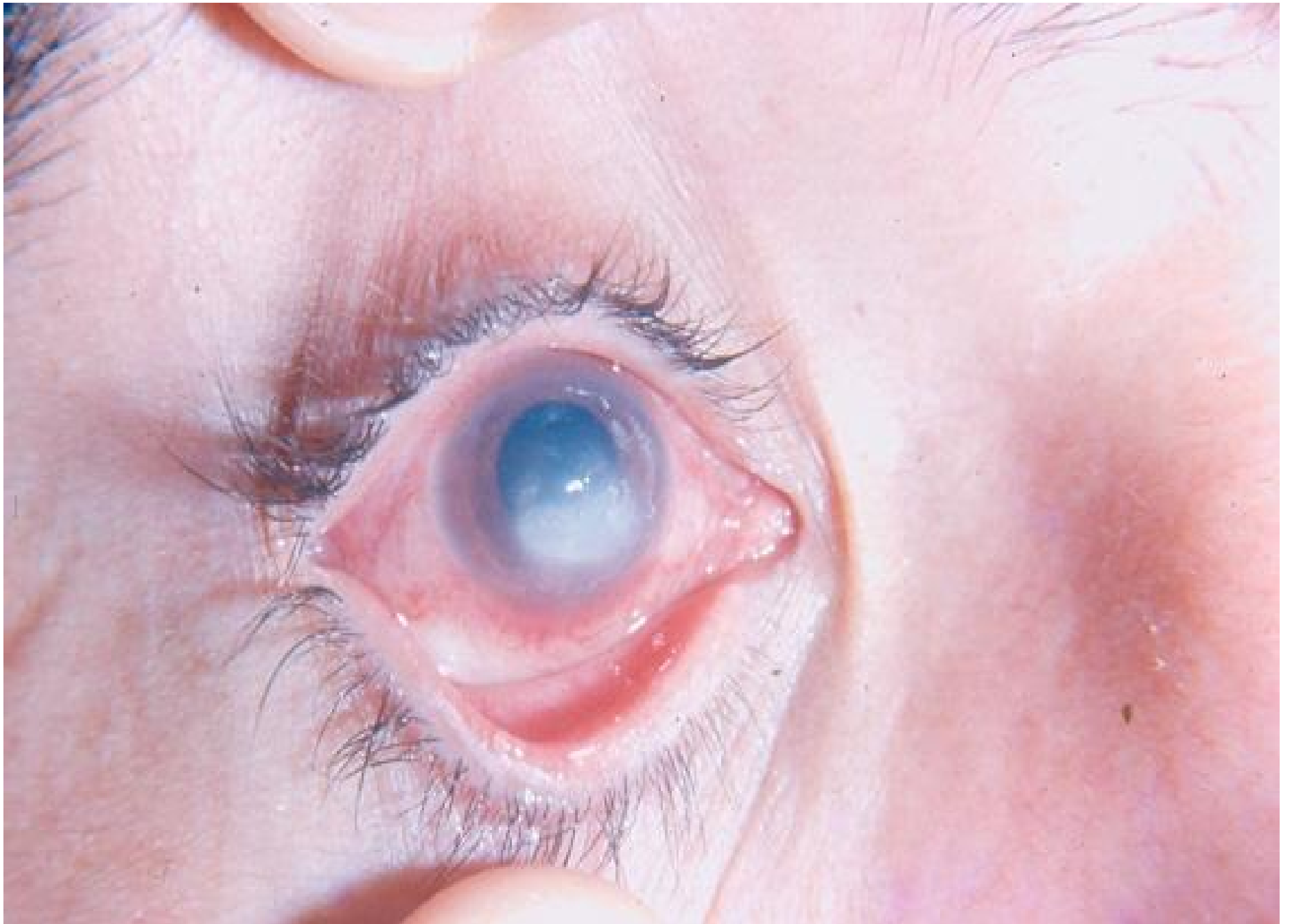HERPES  
SALATU

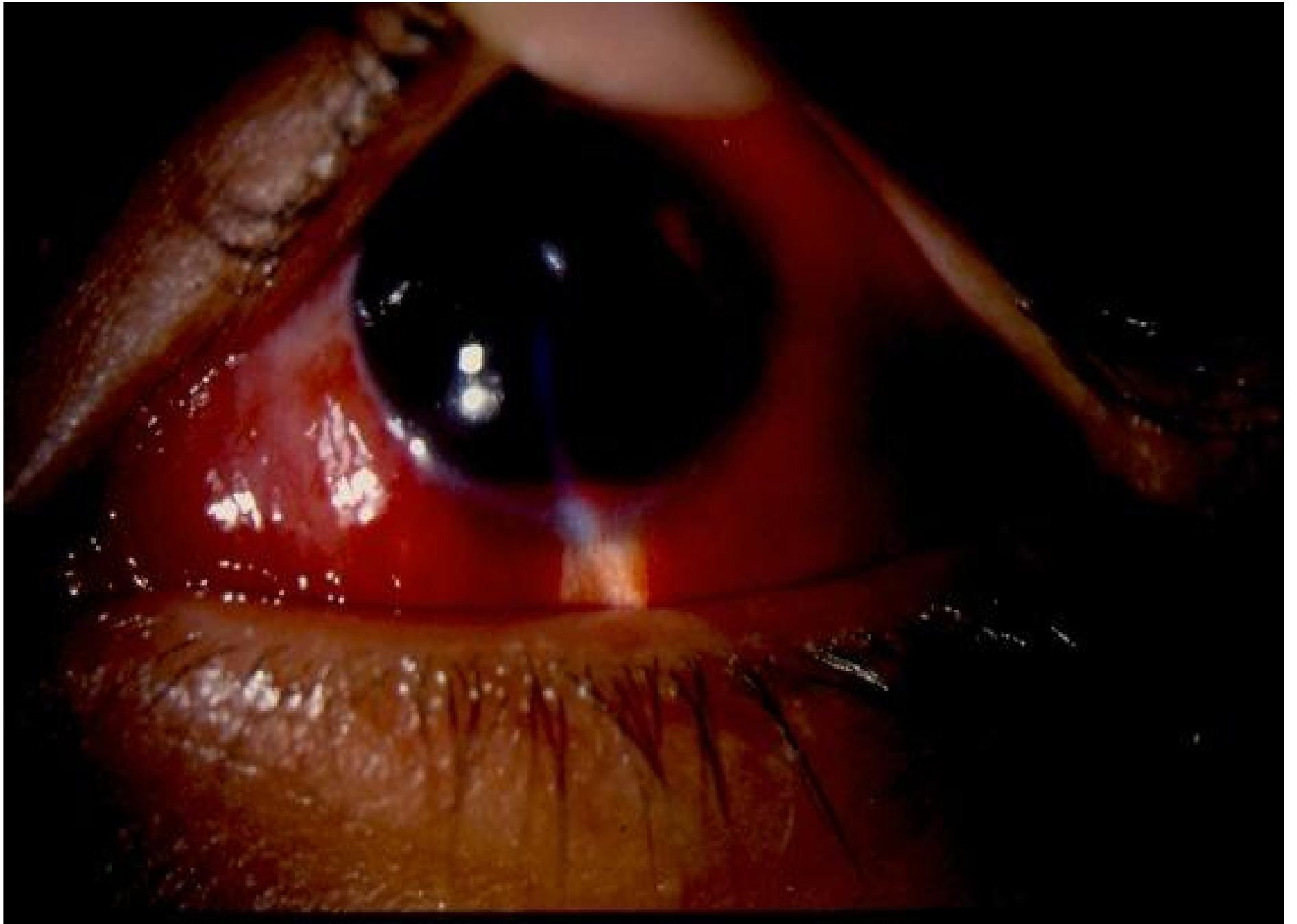

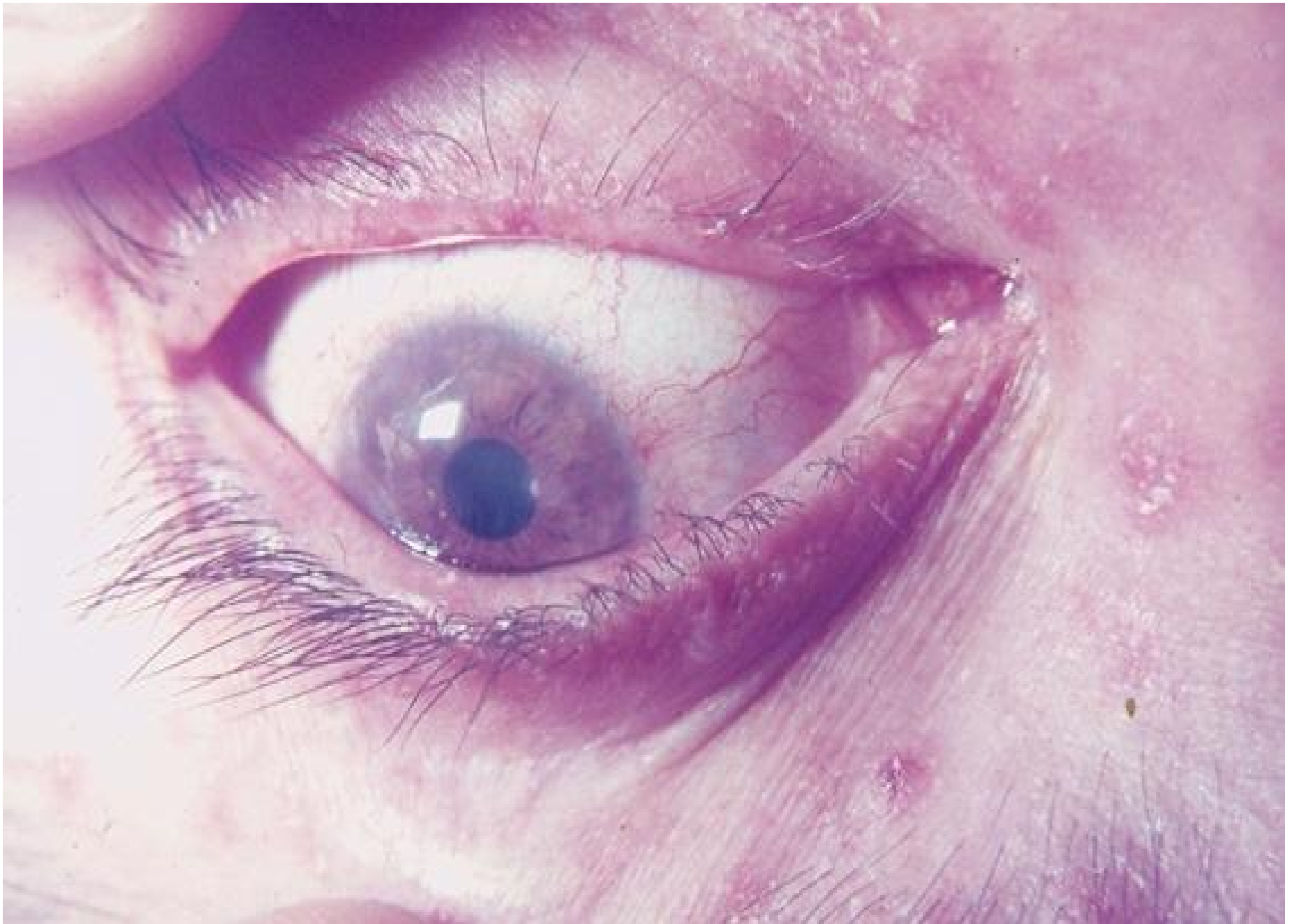22













# SINTOMAS

⊗	GL.	IC	QUER.	C.BAC	C.VIR.	C.AL
⊗ V.Borrosa	+++	++	+++	0	0	0
⊗ Dolor	+++	++	++	0	0	0
⊗ Fotofobia	+	++	++	0	0	0
⊗ Halos	+++	0	0	0	0	0
⊗ Exudados	0	0	++	+++	++	+
⊗ Ardor	0	0	0	0	0	++++

# SIGNOS

	GL.	I.C.	QUER.	C.BAC.	C.VIR.	C.ALER
⊕ C.ciliar	++	++	+++	0	0	0
⊕ C.conj.	++	++	++	+++	++	+
⊕ Edema C.	+++	0	++			
⊕ Pupila	midr.	Mios.				
⊕ C.A.	estrc					
⊕ P.O.	++++					
⊕ Secreción				++++	++	+
⊕ adenopatía					+	